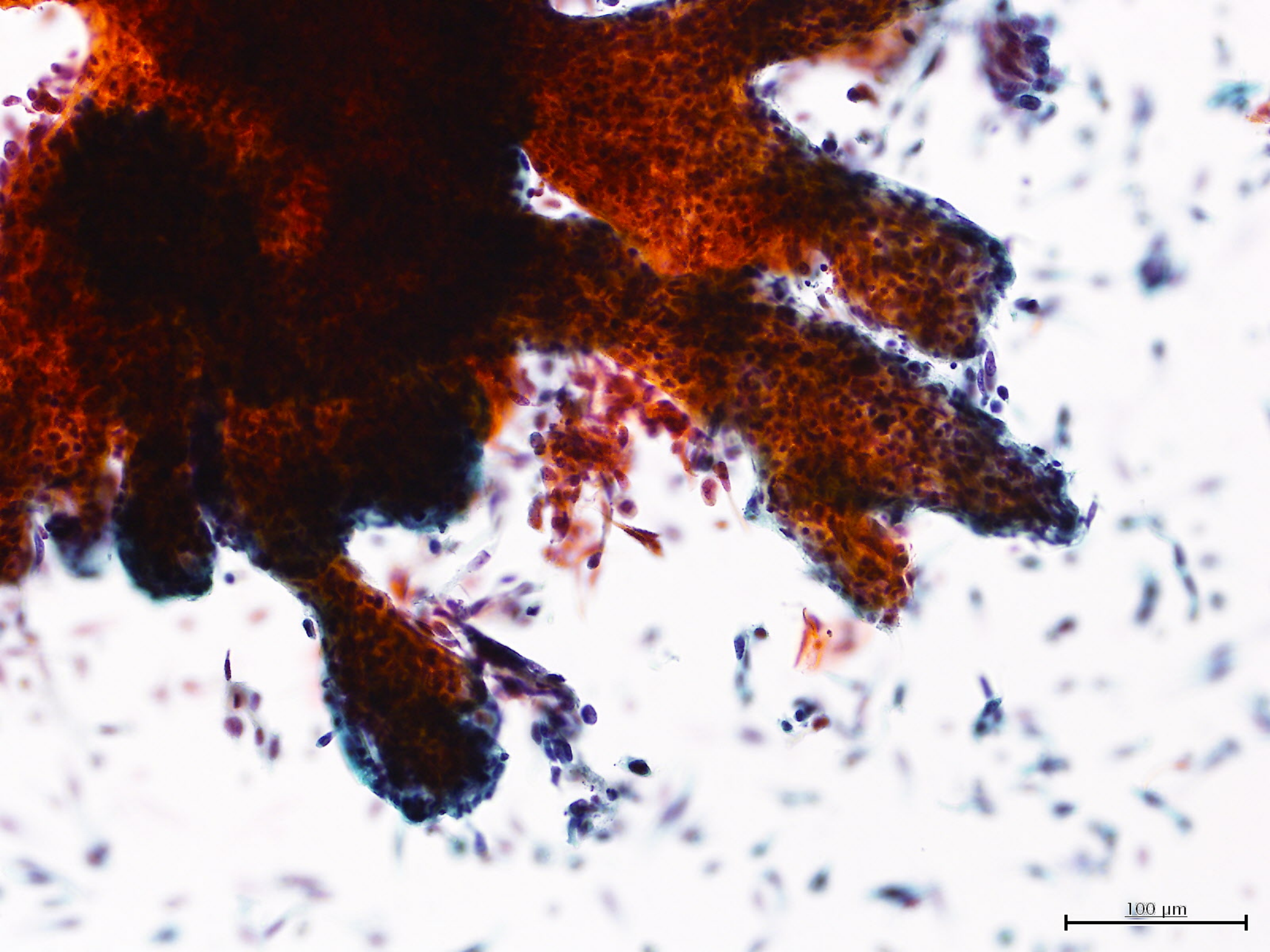
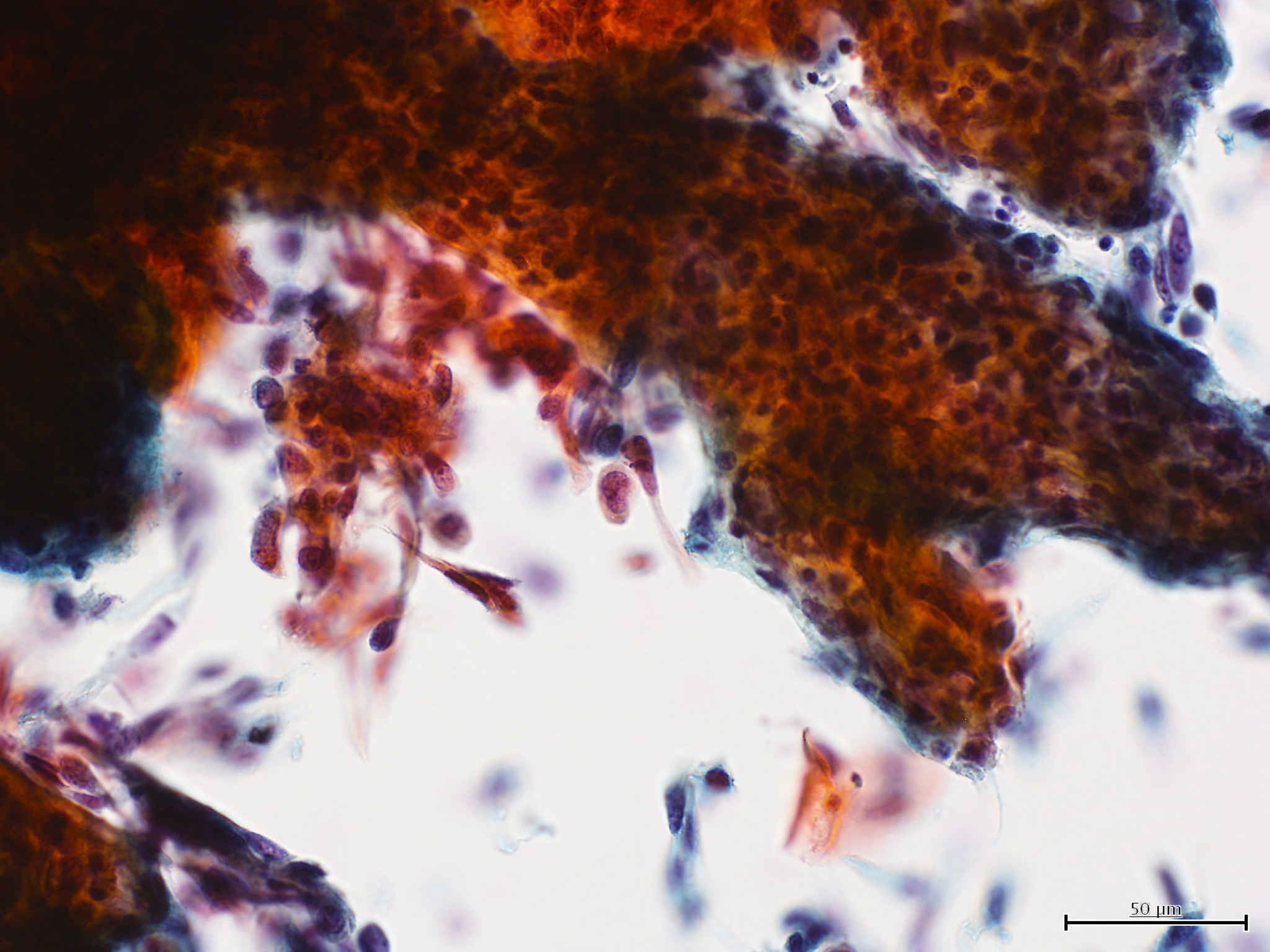


症例1

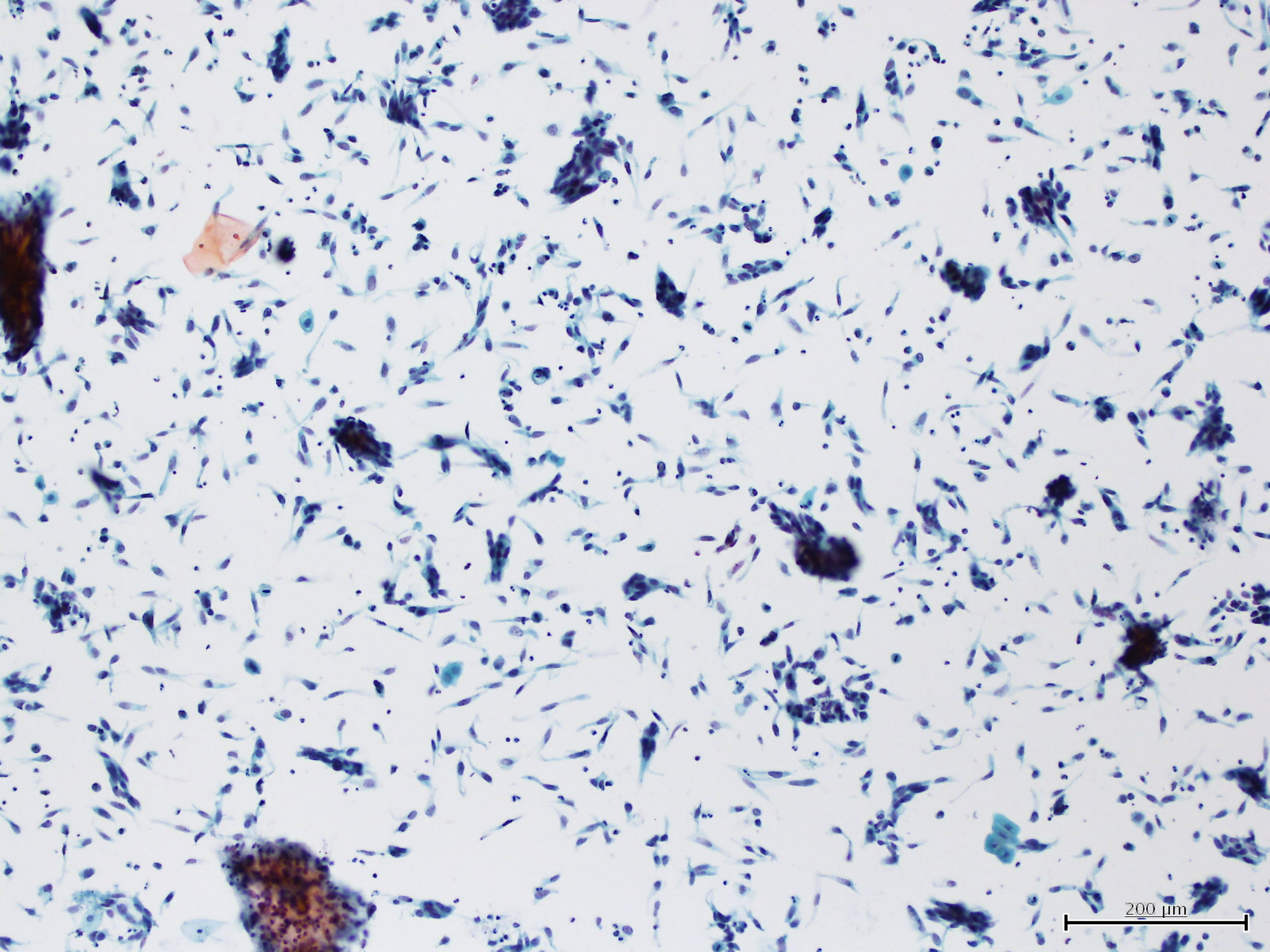
組織型の推定が困難であった婦人科の一例

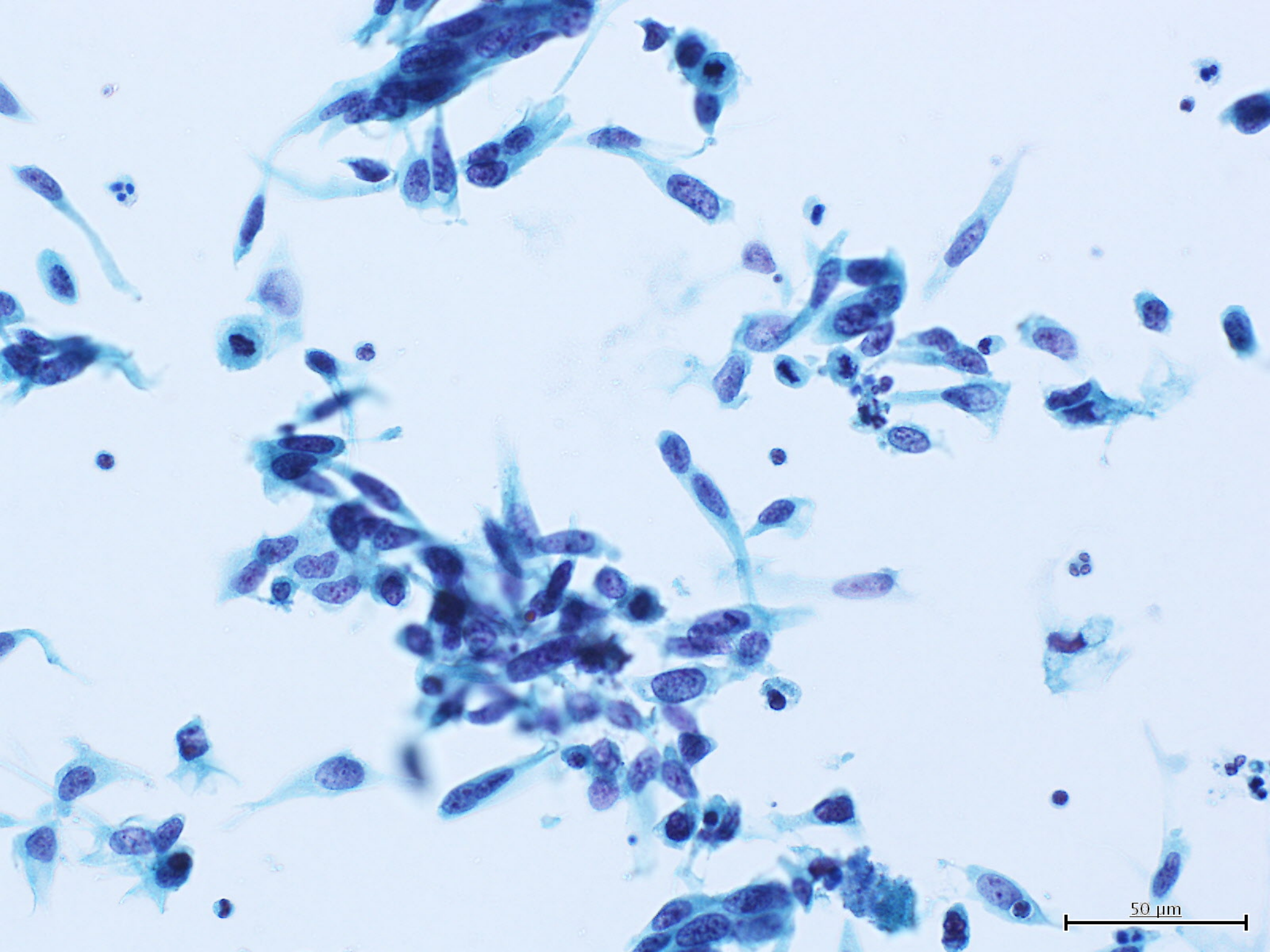


100 μm

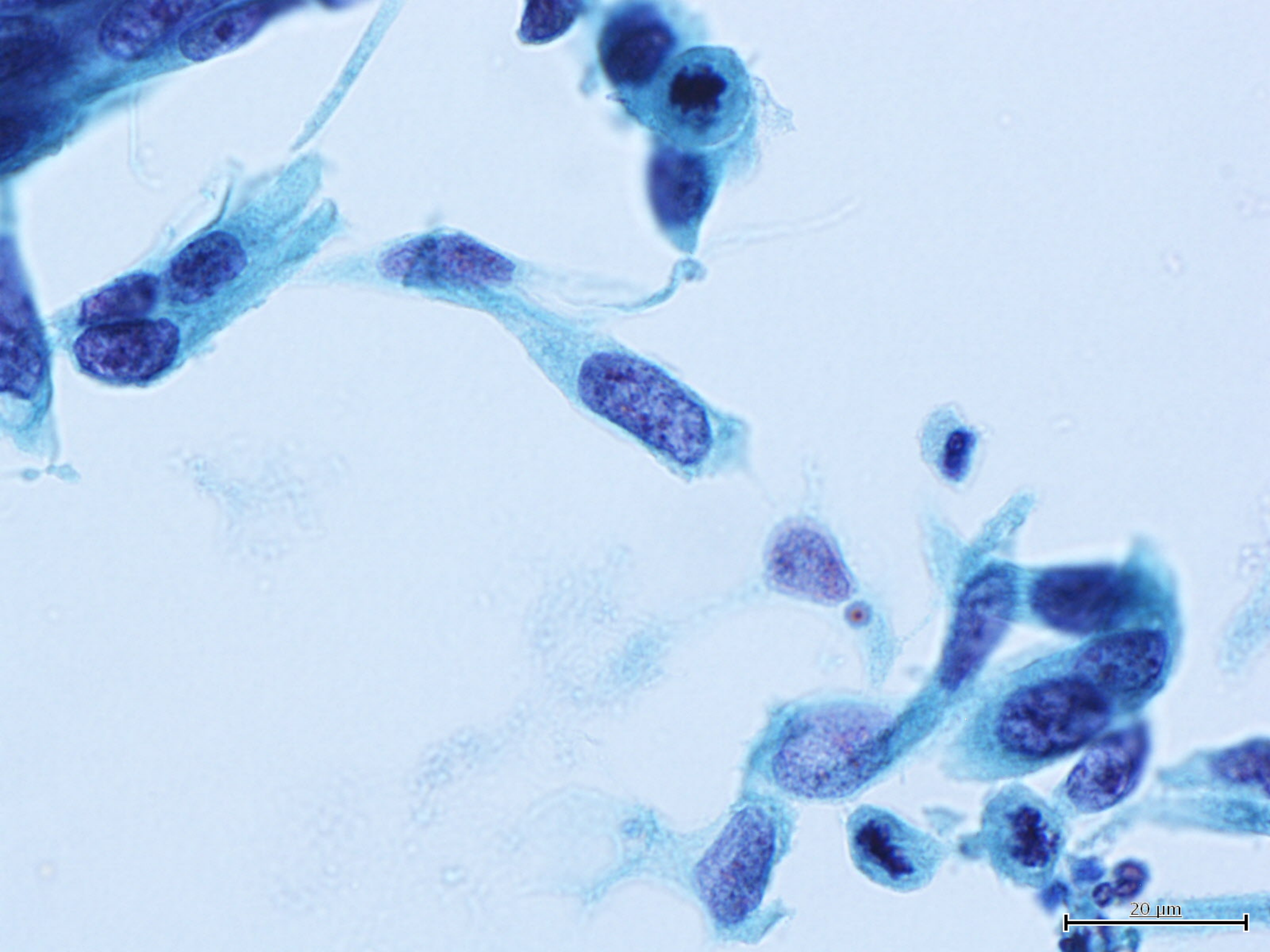


50 μm





50 μ m



20 μm