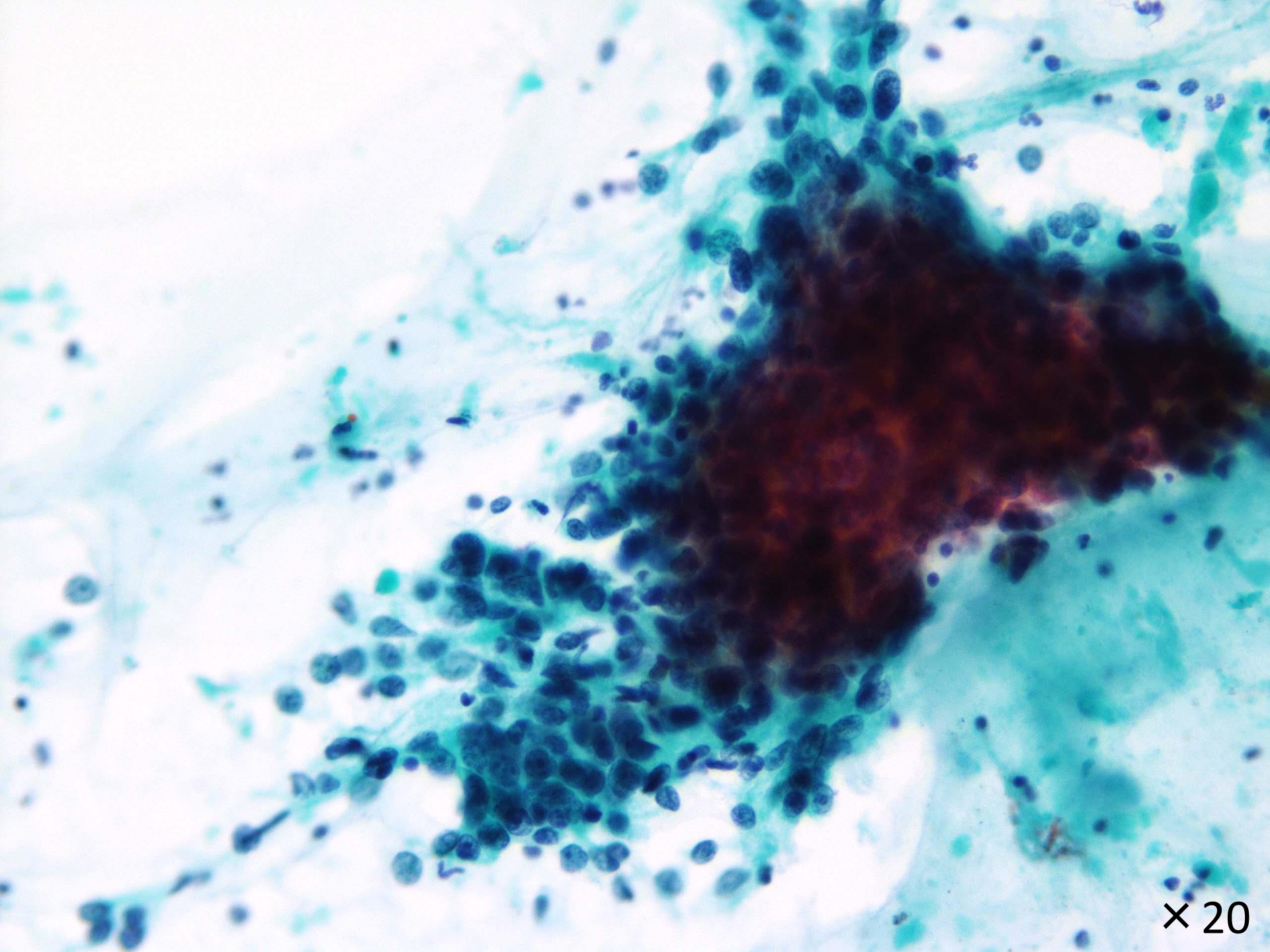


細胞診従事者講習会  
症例検討会

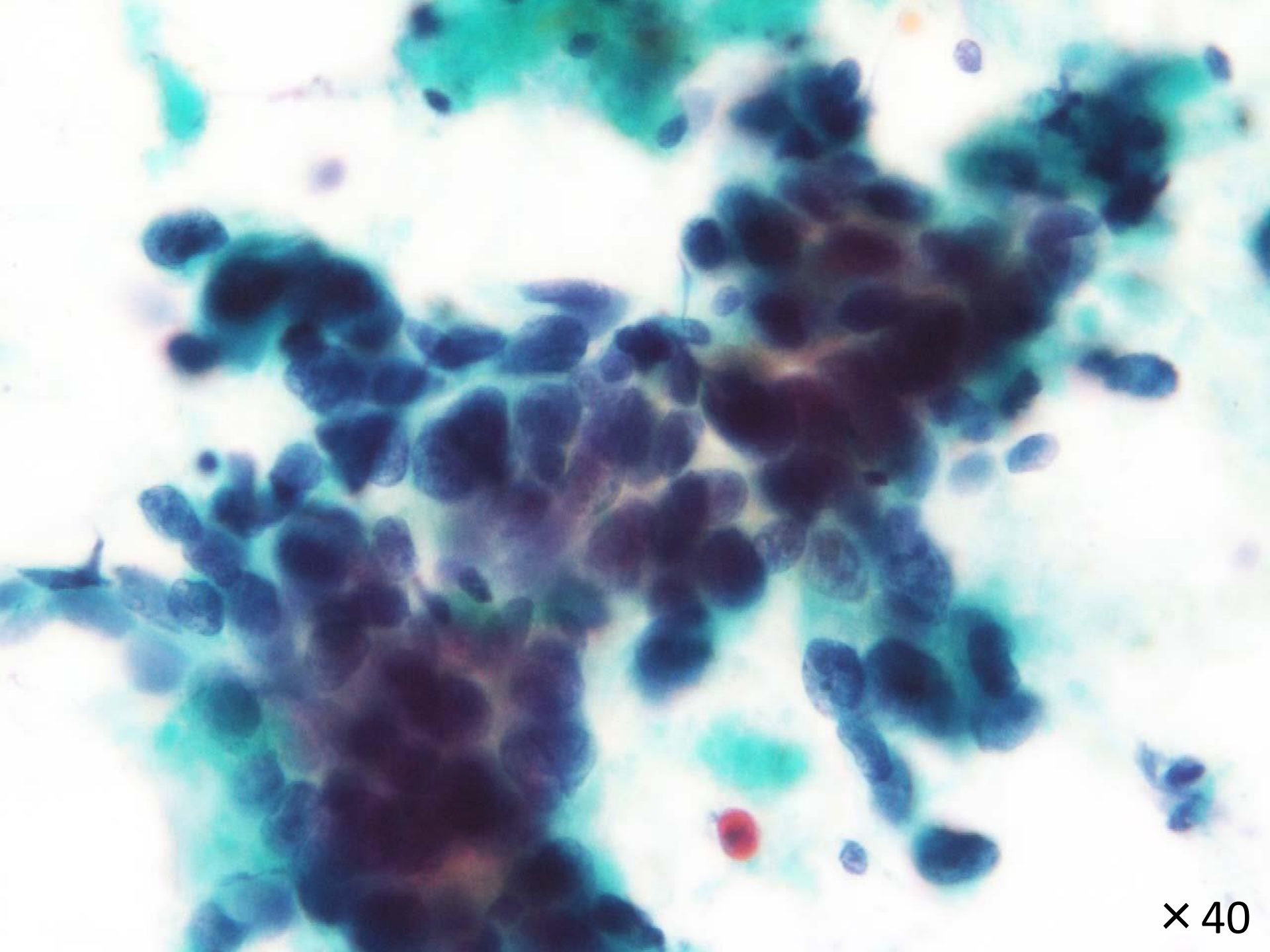
# 症例1

大分赤十字病院  
小平 七菜

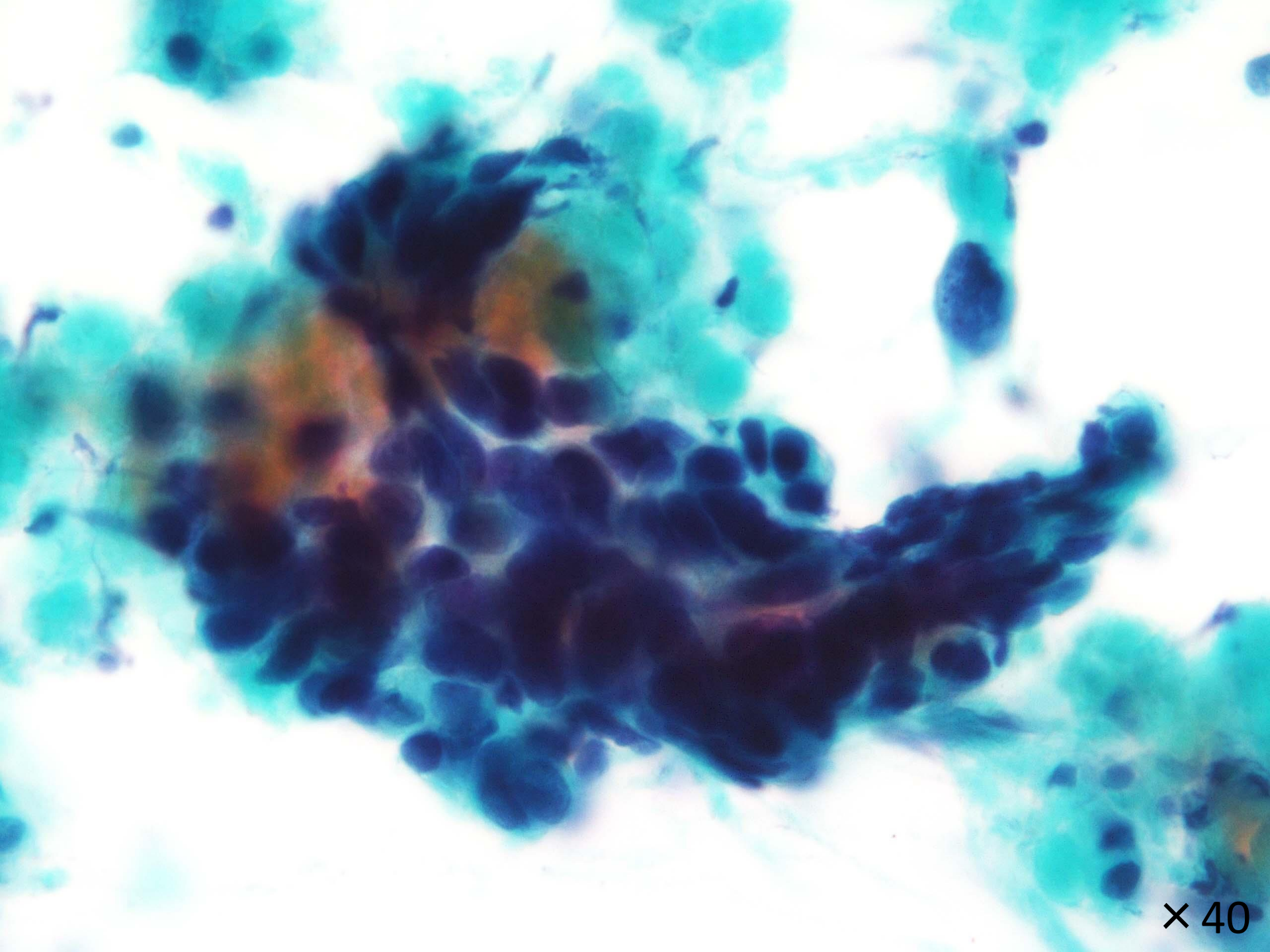
- 症 例：60歳代、男性
- 検査材料：気管支擦過（ブラシ）
- 病 歴：胸部レントゲンで左下肺野に異常陰影、  
胸部CT検査で左肺舌区中枢側にLK様  
所見を認め、精査・加療のため紹介受診



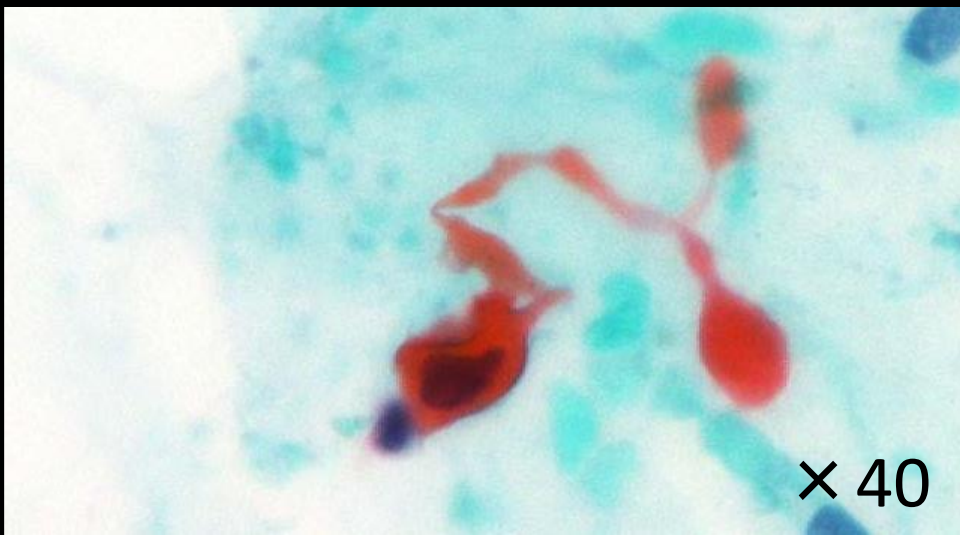
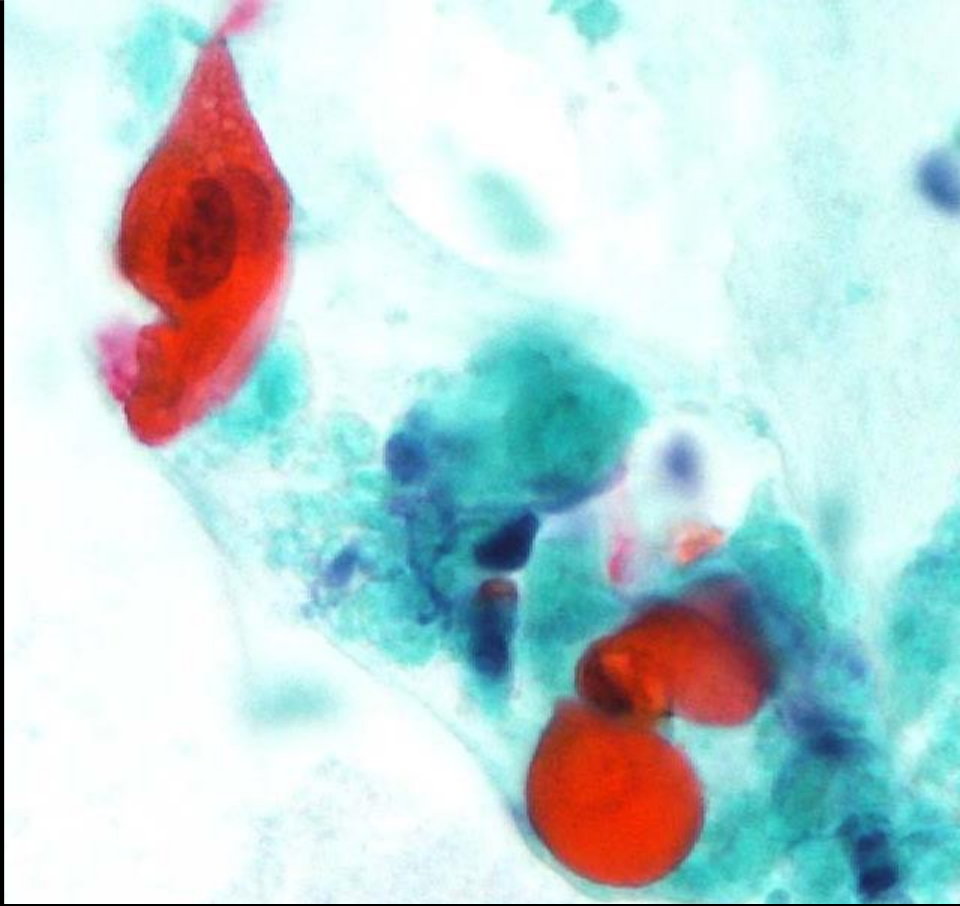
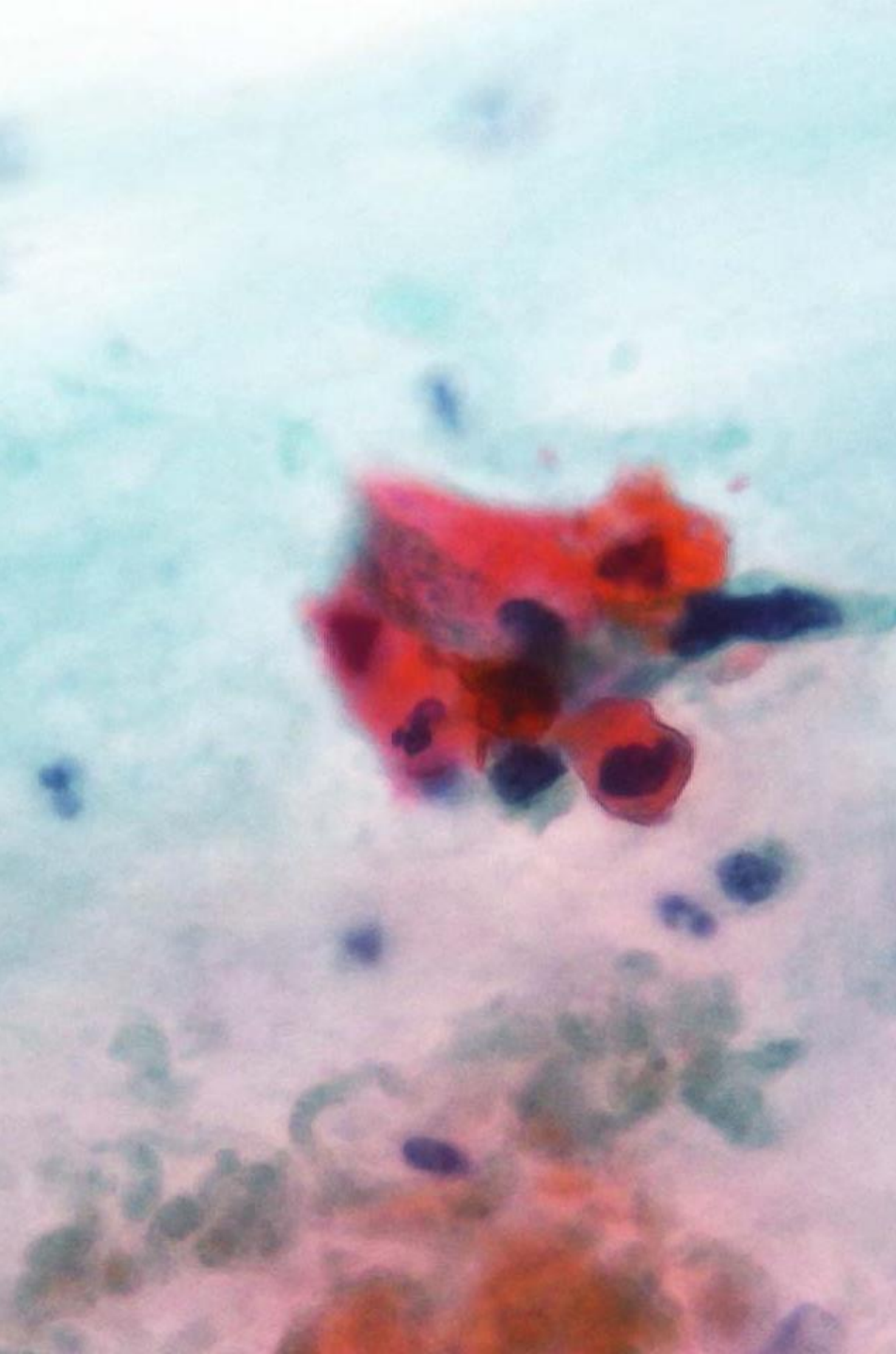
× 20



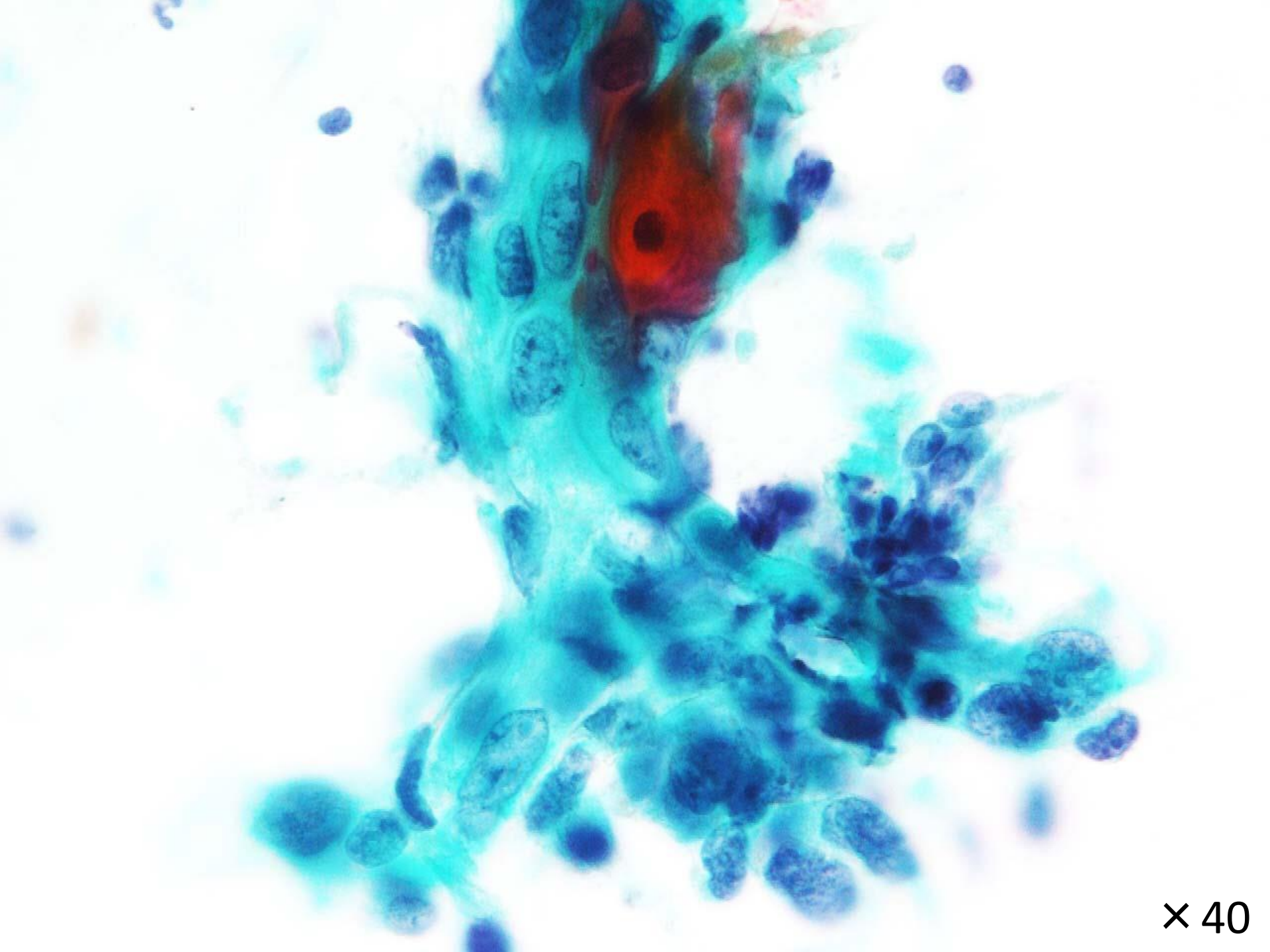
× 40



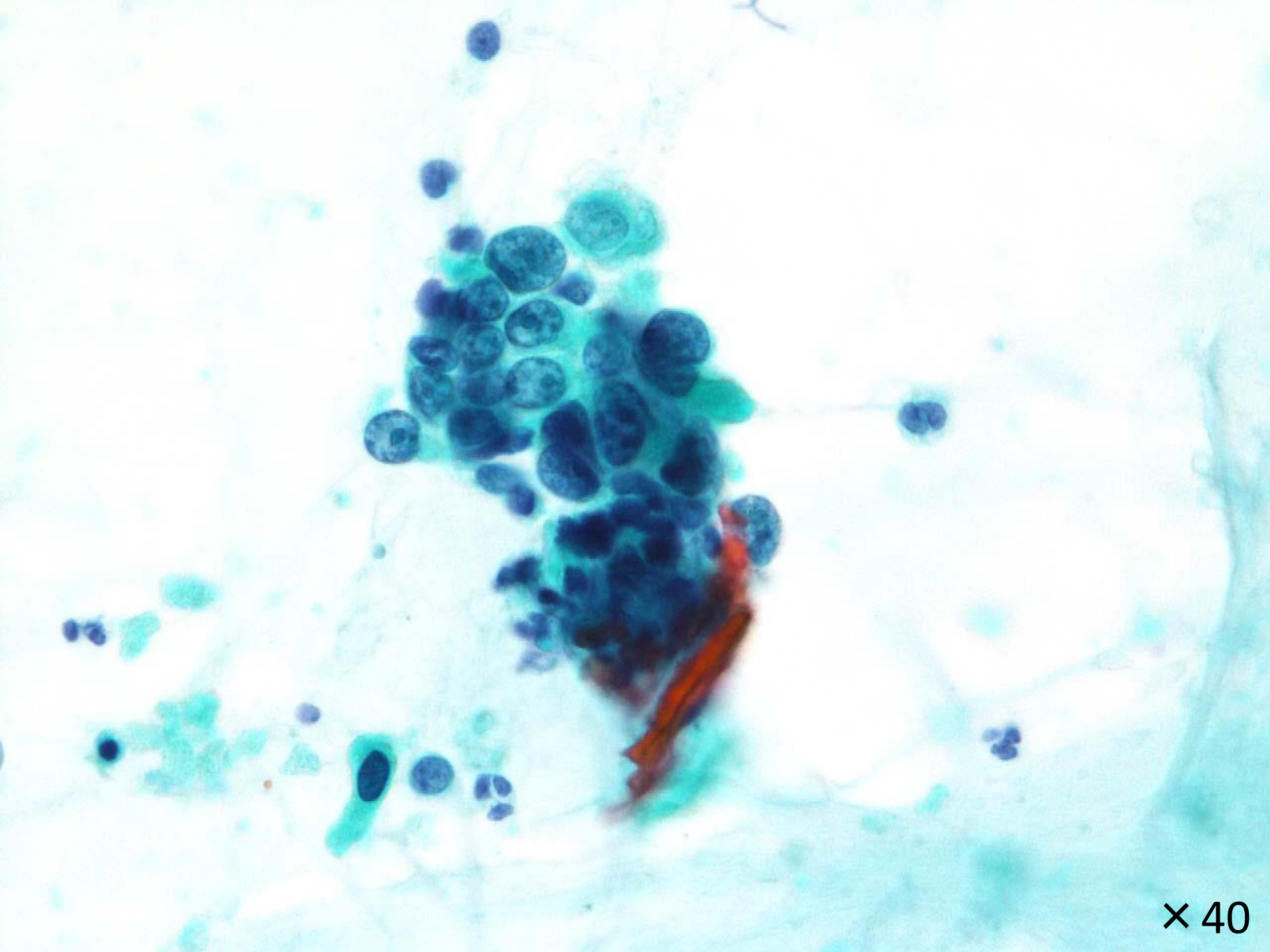
× 40



× 40

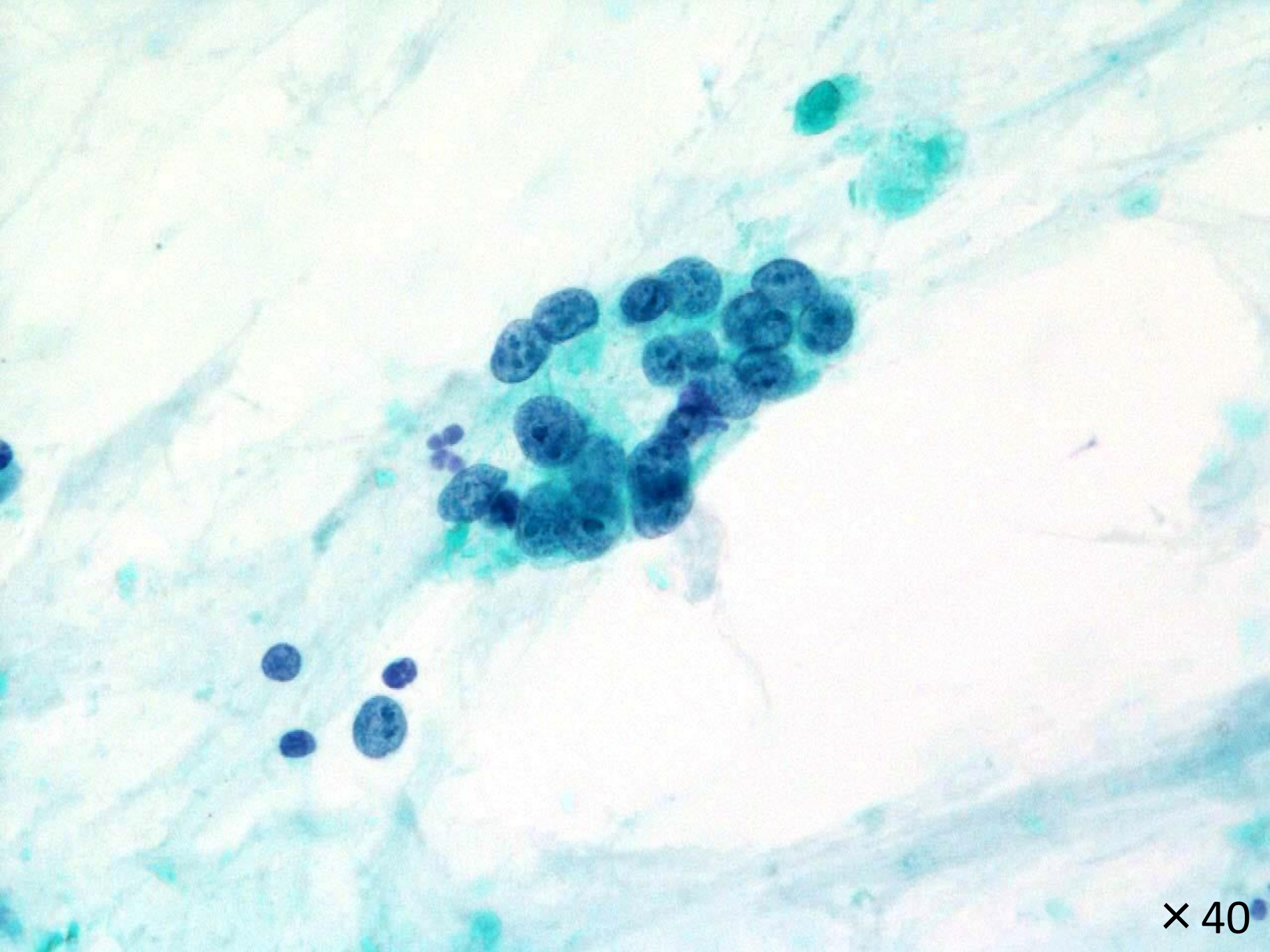


× 40

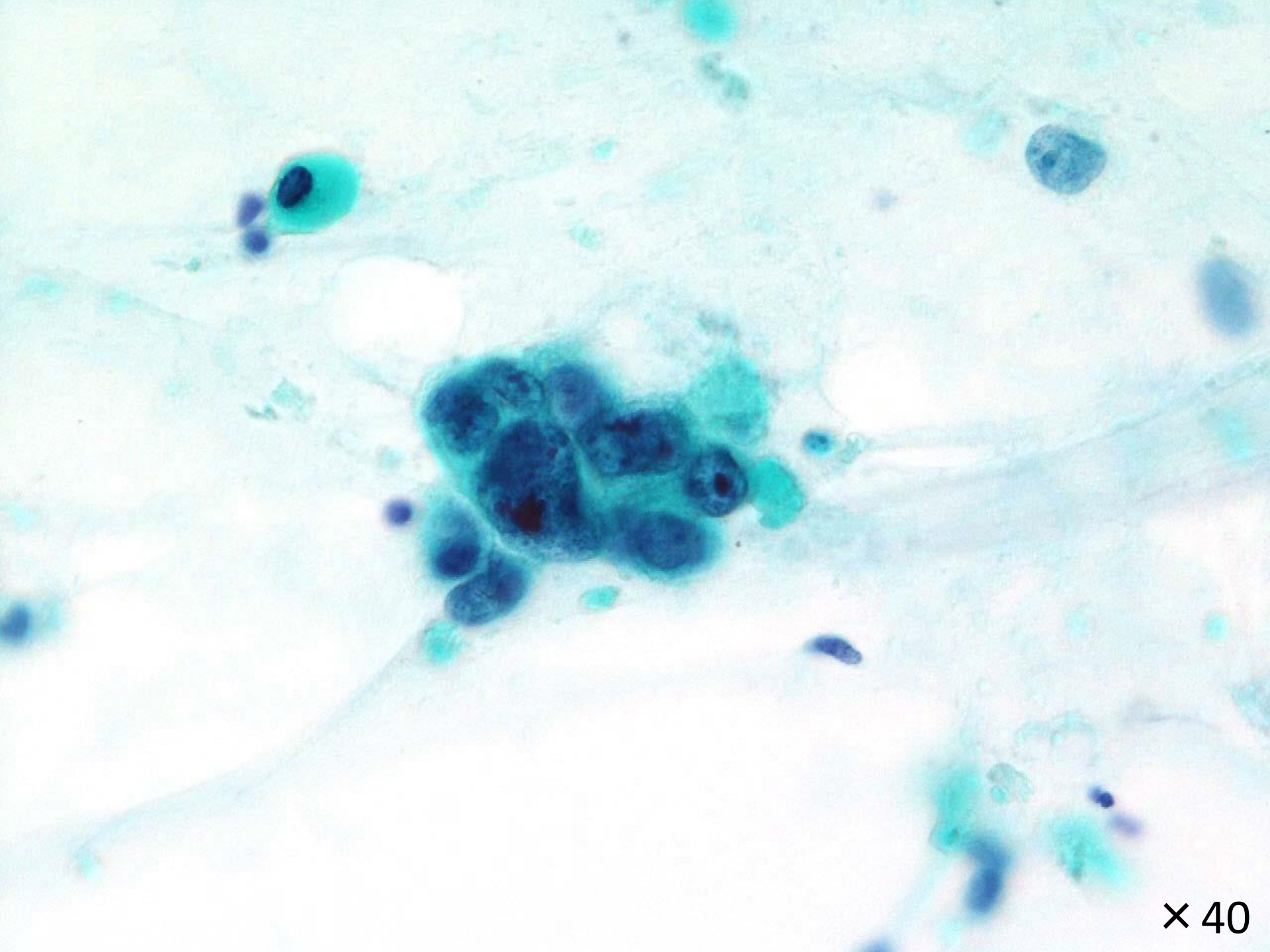


× 40

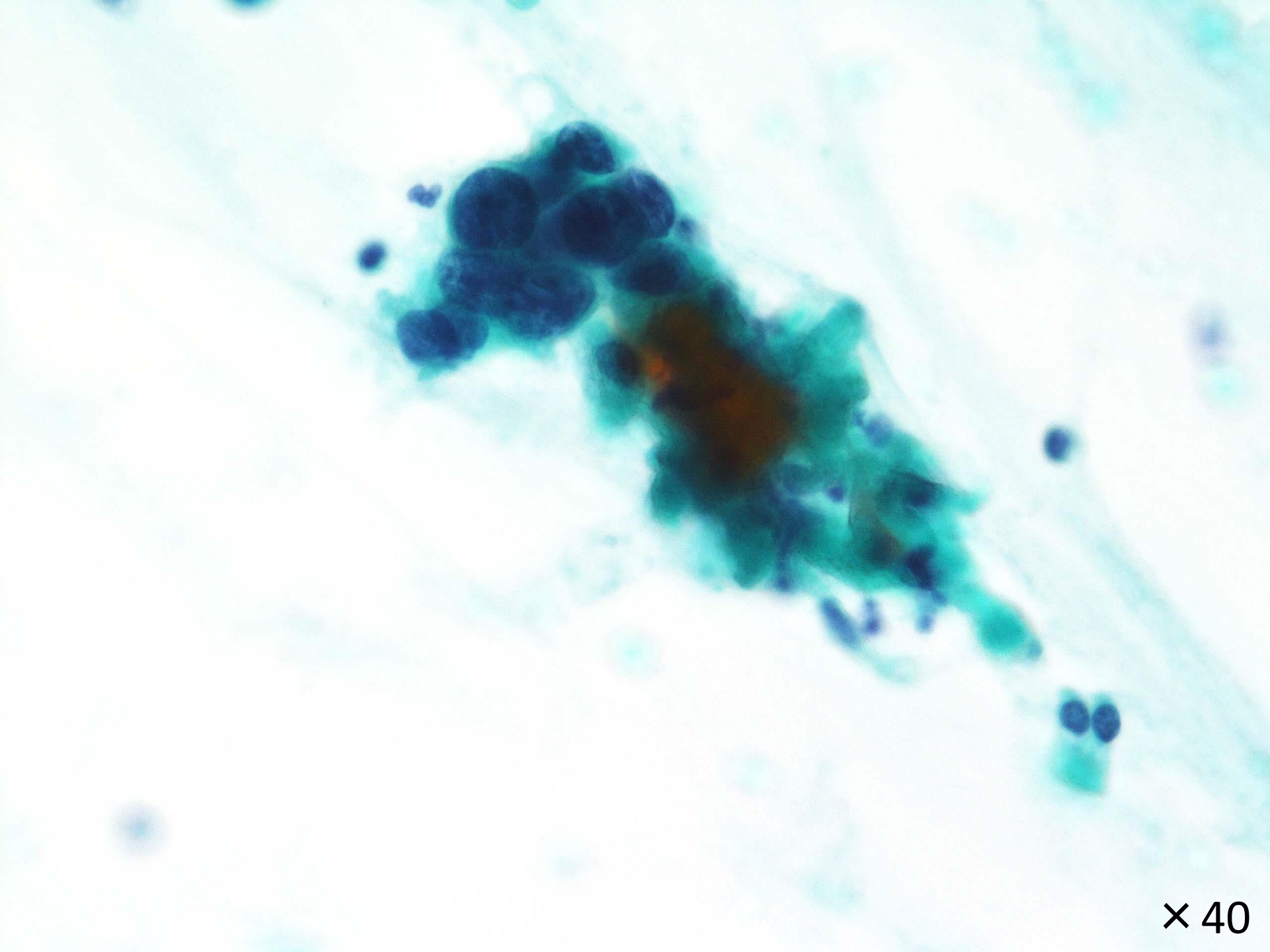




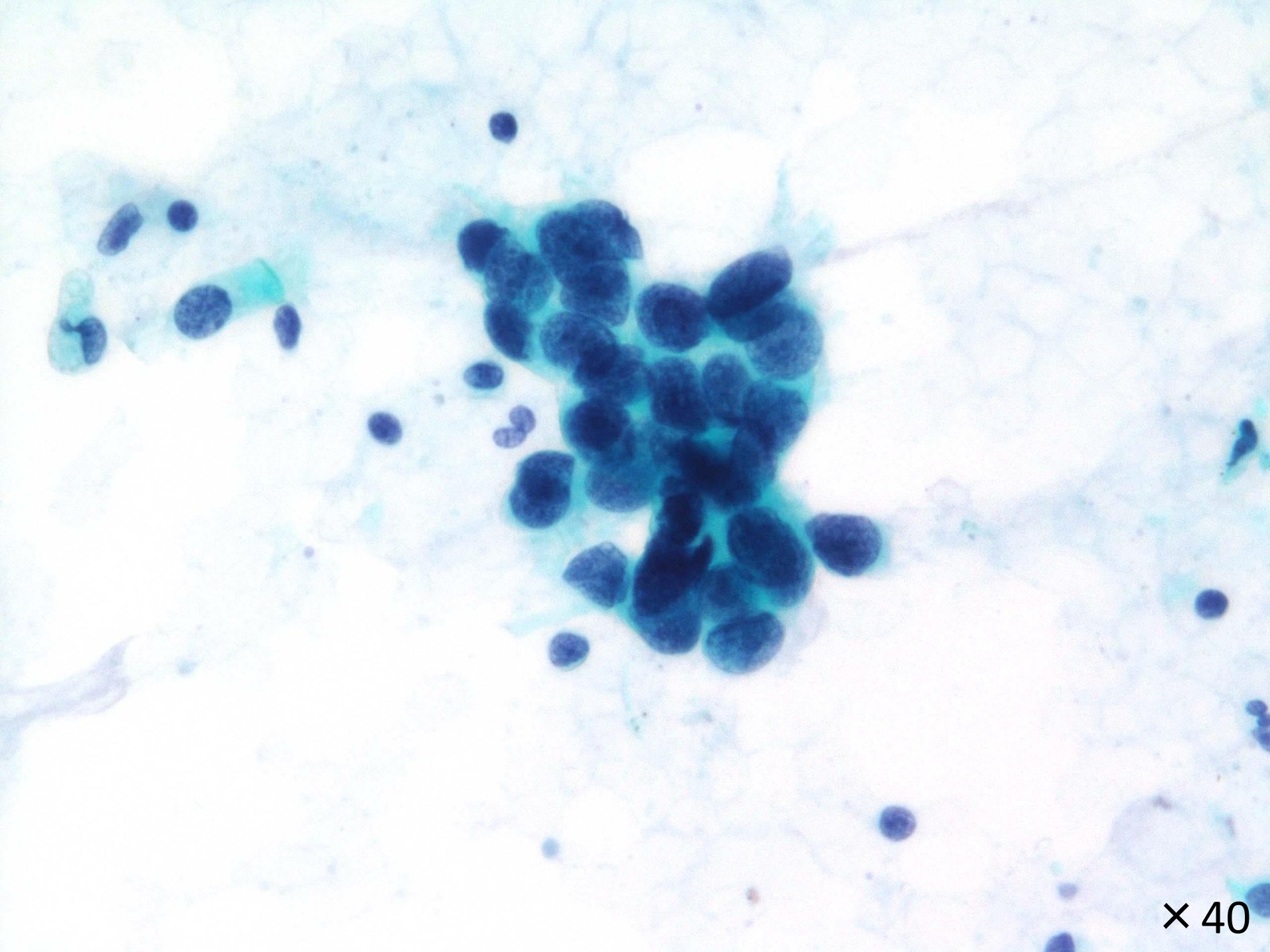
× 40



× 40



× 40



× 40