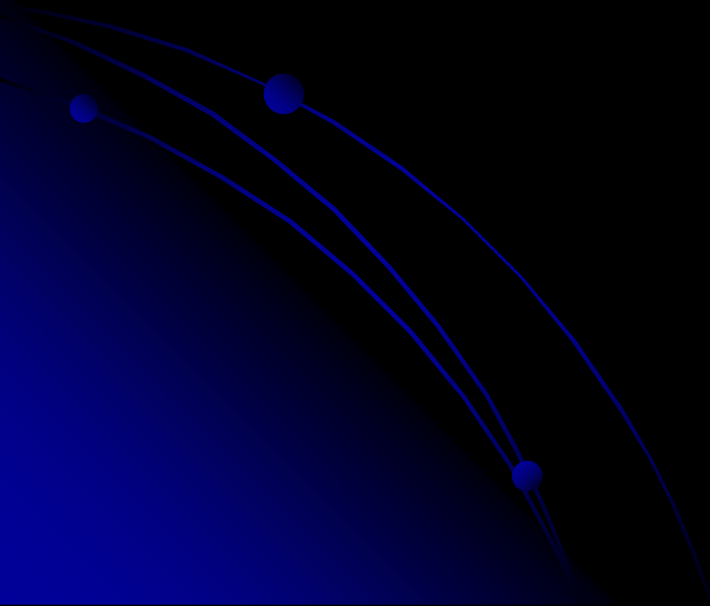


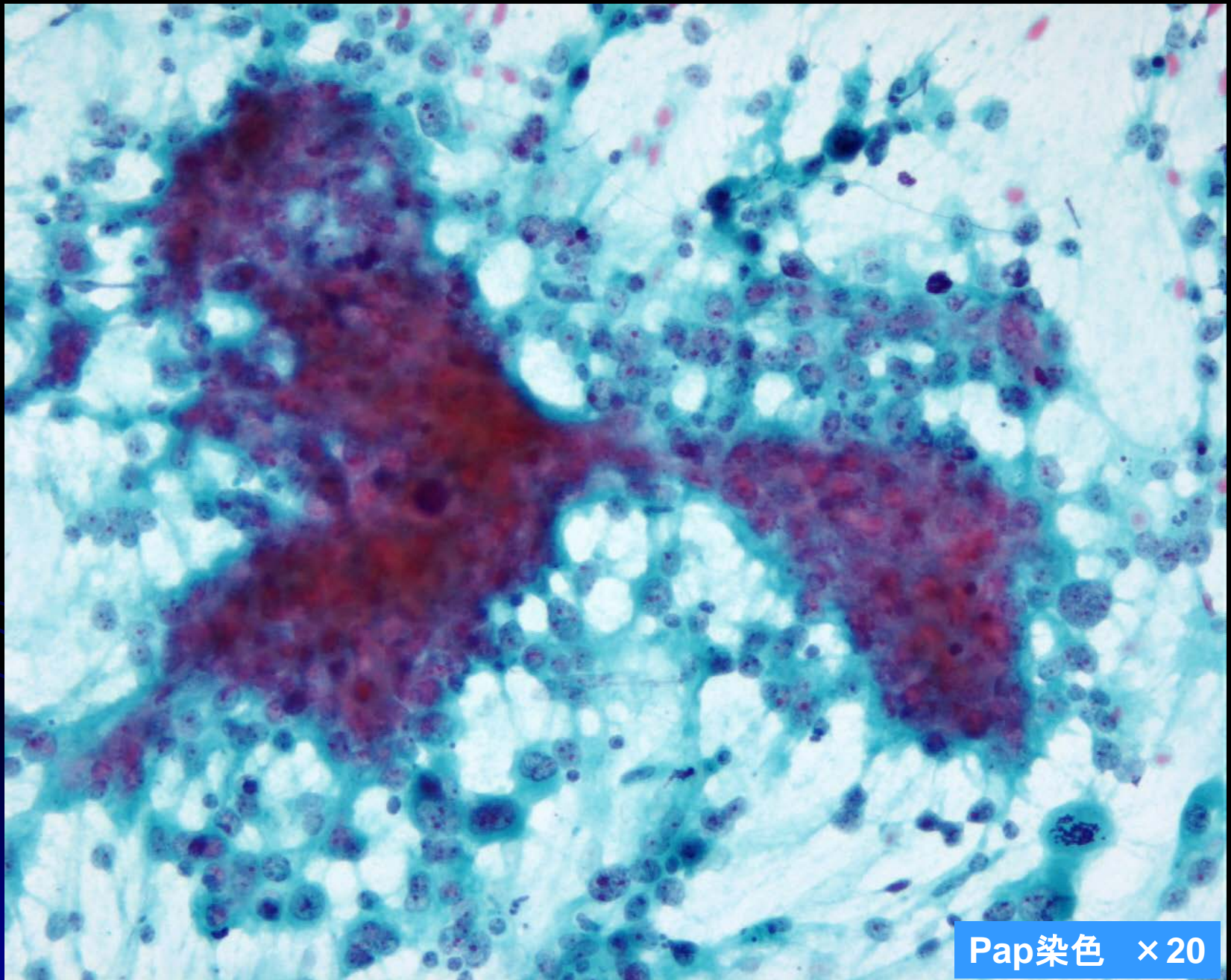
# 症例

年齢・性別：50代 女性

材料：迅速時乳腺腫瘍穿刺材料

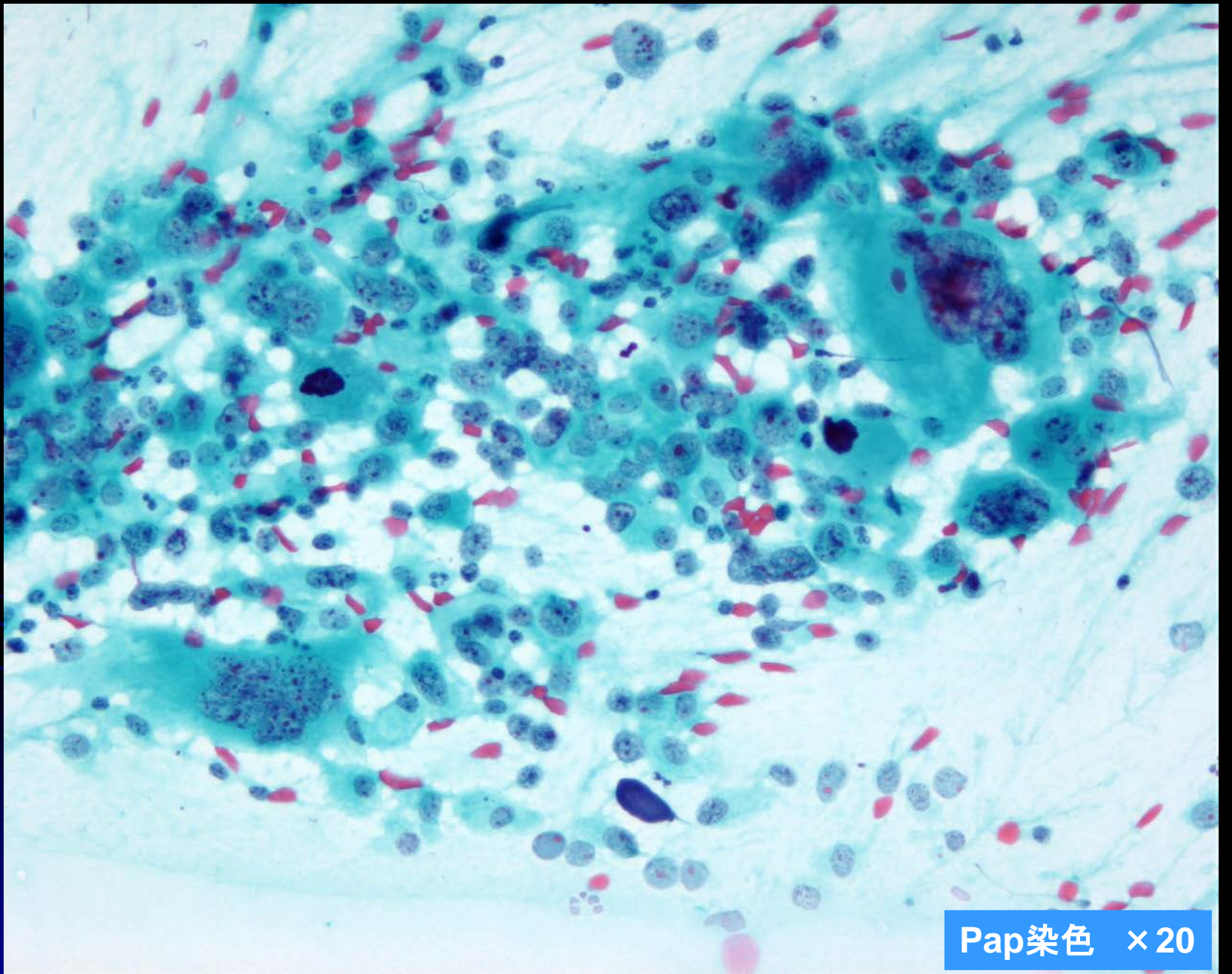
臨床所見：右乳腺C領域に1.5cmのmassを認める。





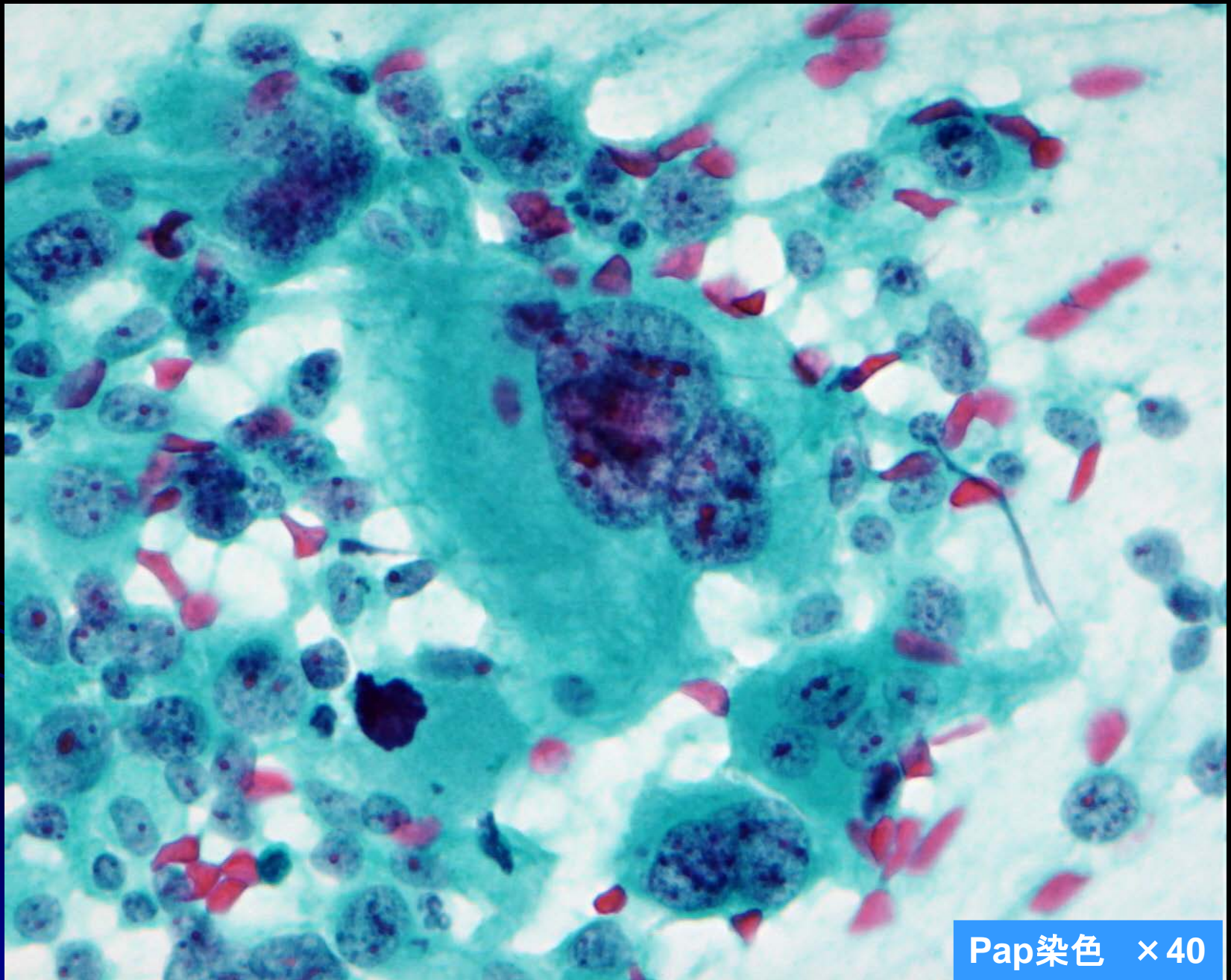
Pap染色 × 20





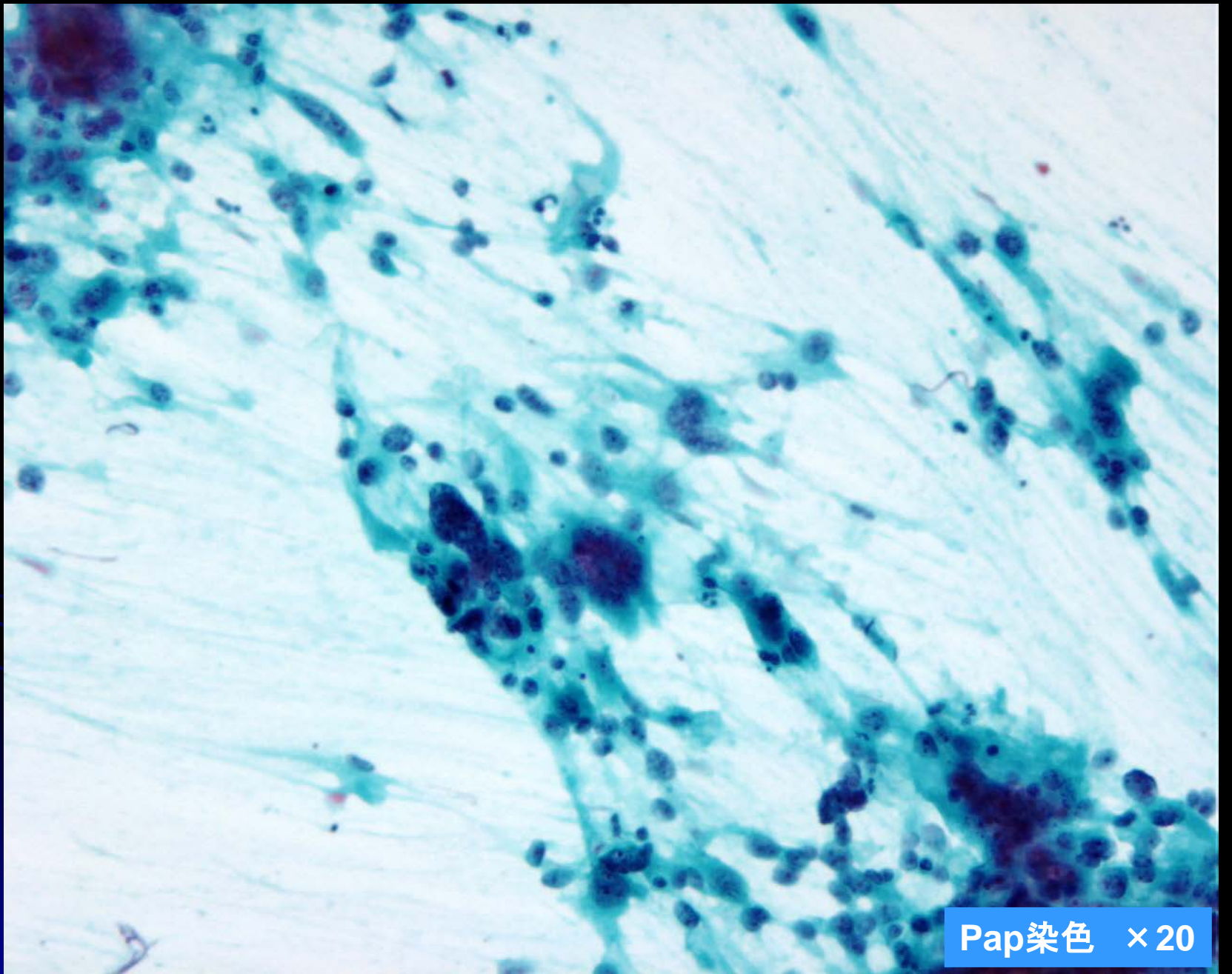
Pap染色 × 20





Pap染色 × 40





Pap染色 × 20