症例　1

- 80代, 女性
- 食道生検捺印標本
- 臨床診断：食道癌の疑い
- 臨床所見：

1-1

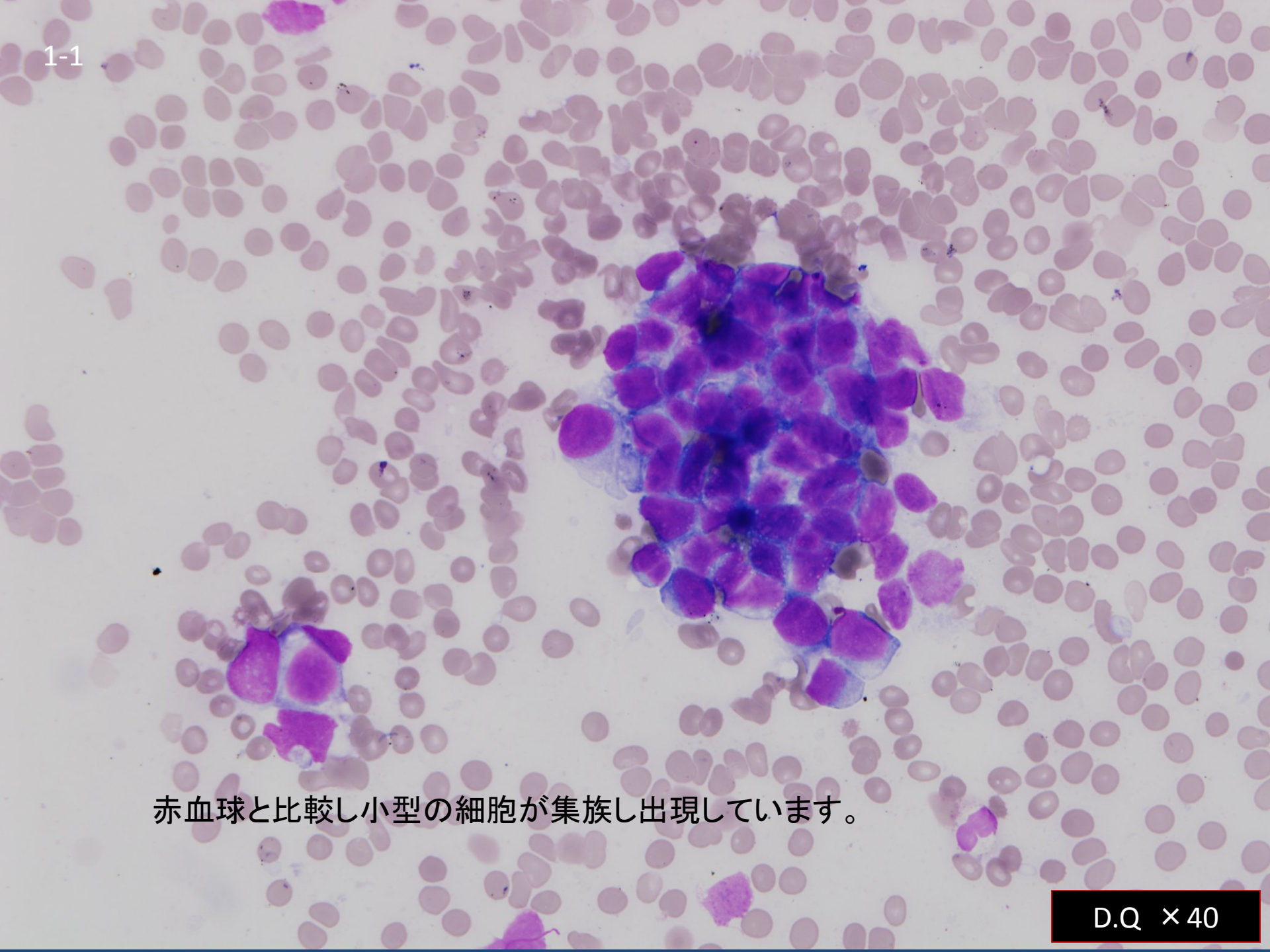

赤血球と比較し小型の細胞が集族し出現しています。

D.Q ×40

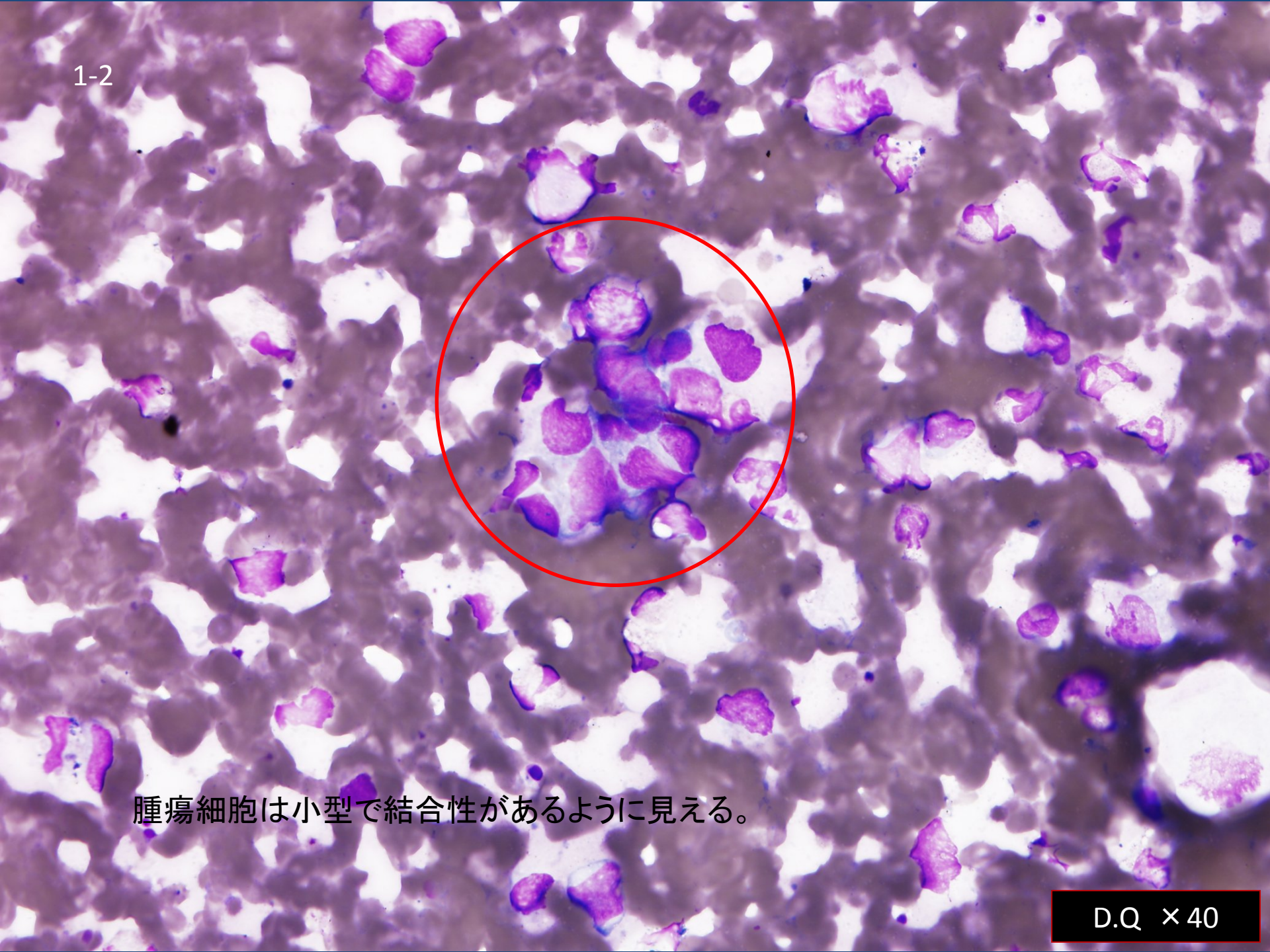
1-2
腫瘍細胞は小型で結合性があるように見える。
D.Q ×40

1-3
核クロマチンの性状は微細で，リンパ球と類似するが木目込み細工様の配列やリボン状配列が見られる。
D.Q ×60

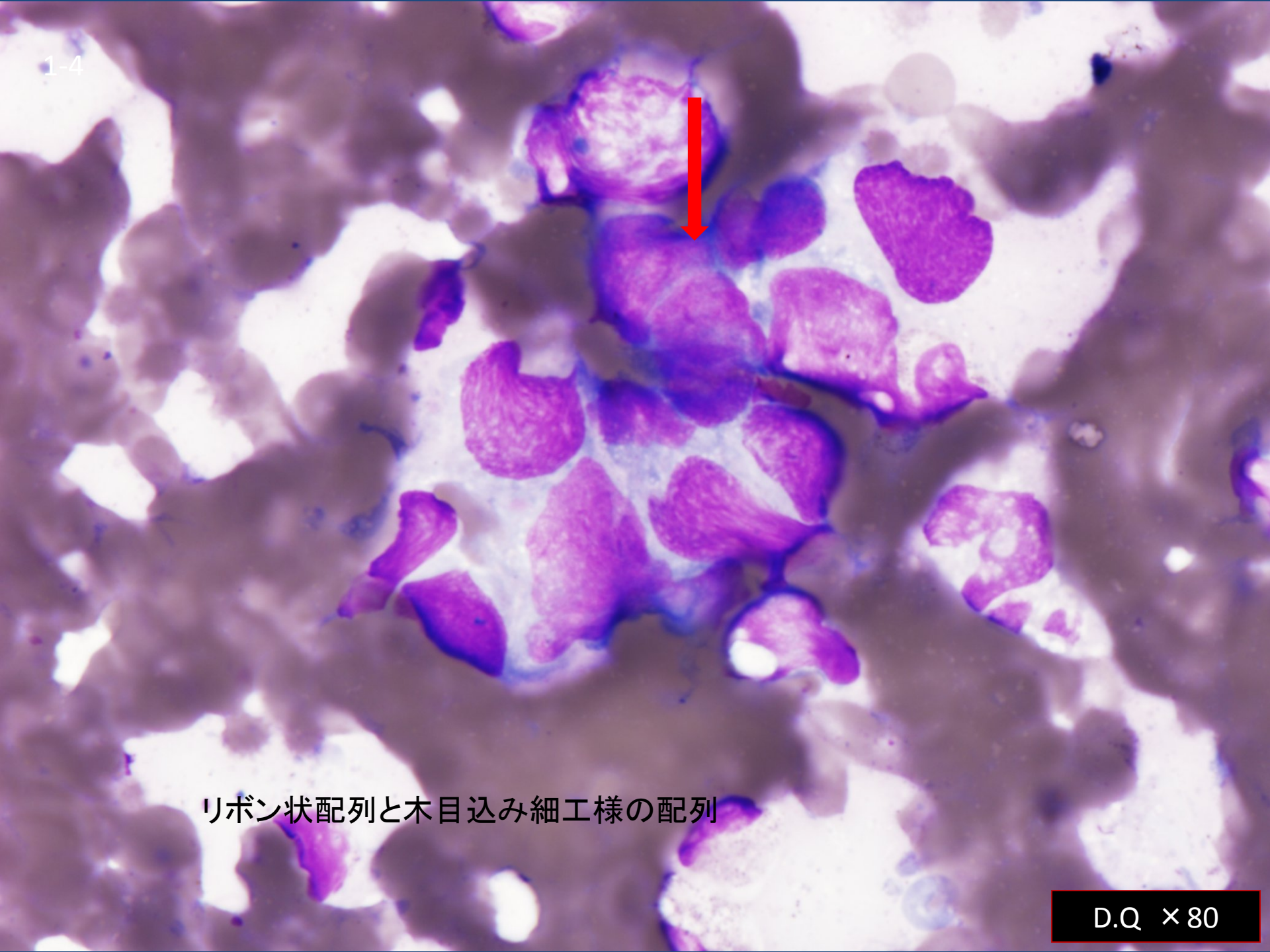
1-4
リボン状配列と木目込み細工様の配列
D.Q ×80

2-4

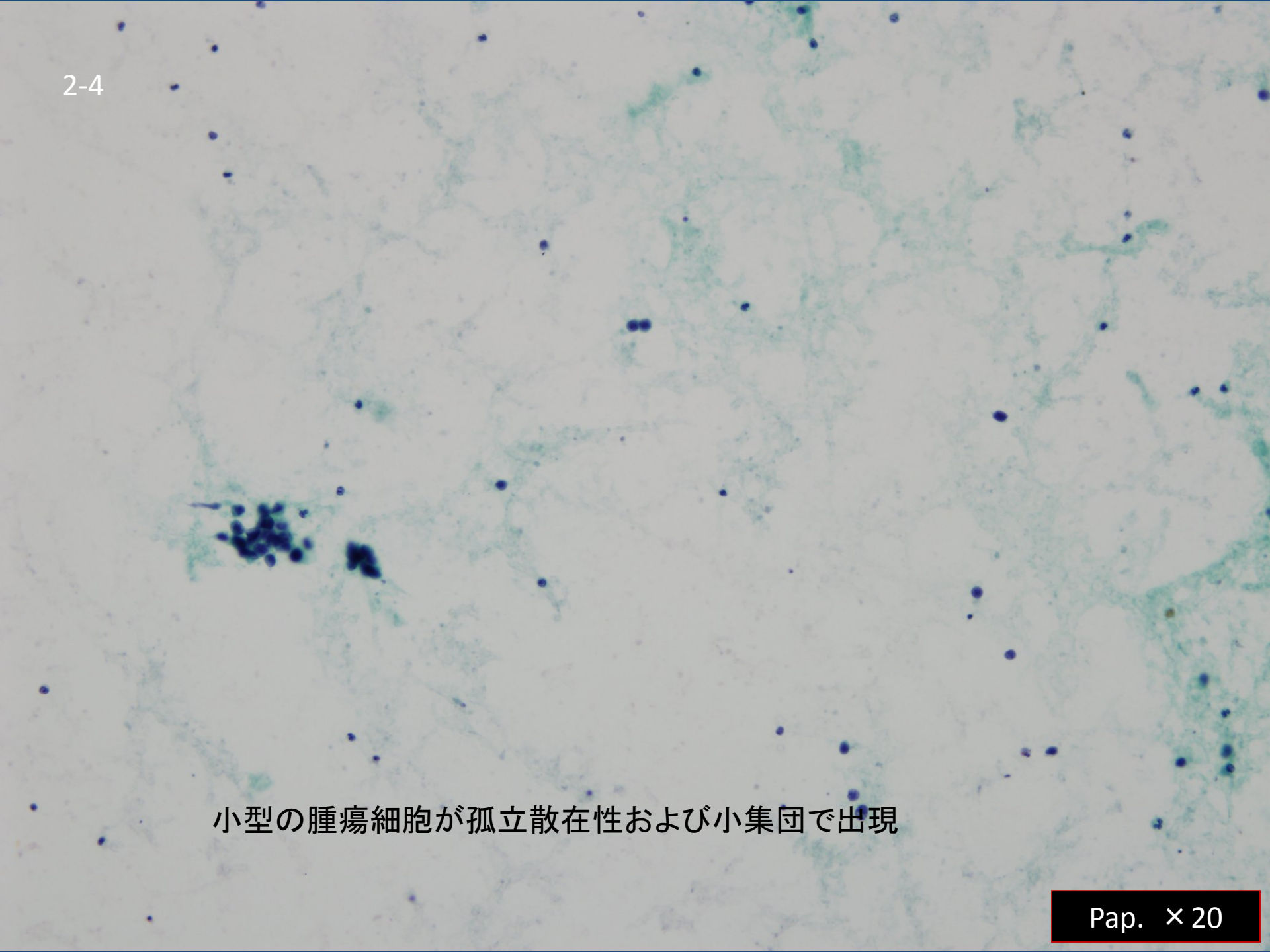

2-L

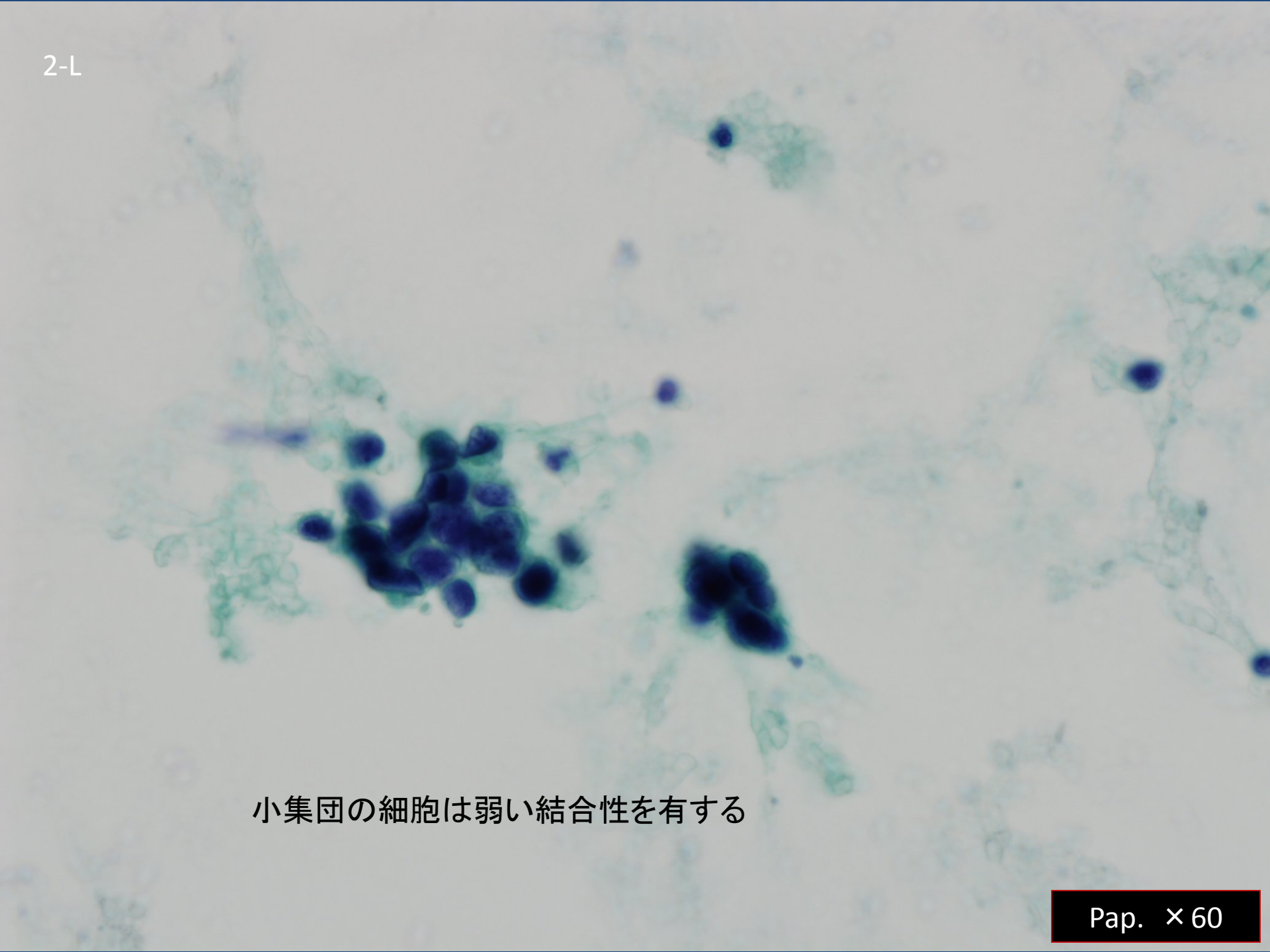

2-L

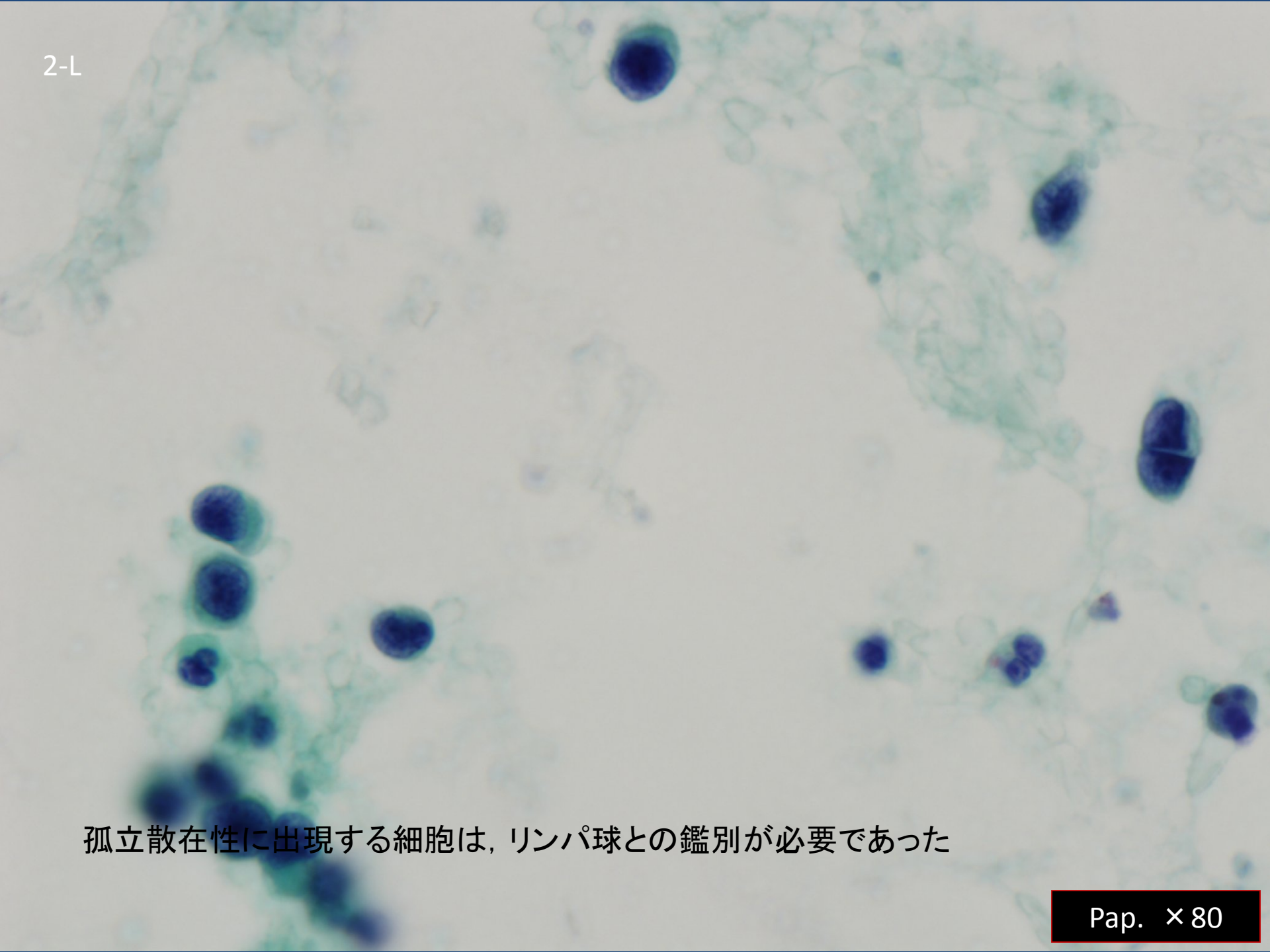

孤立散在性に出現する細胞は，リンパ球との鑑別が必要であった

Pap.　×80

細胞診断

- Small cell carcinoma, most likely

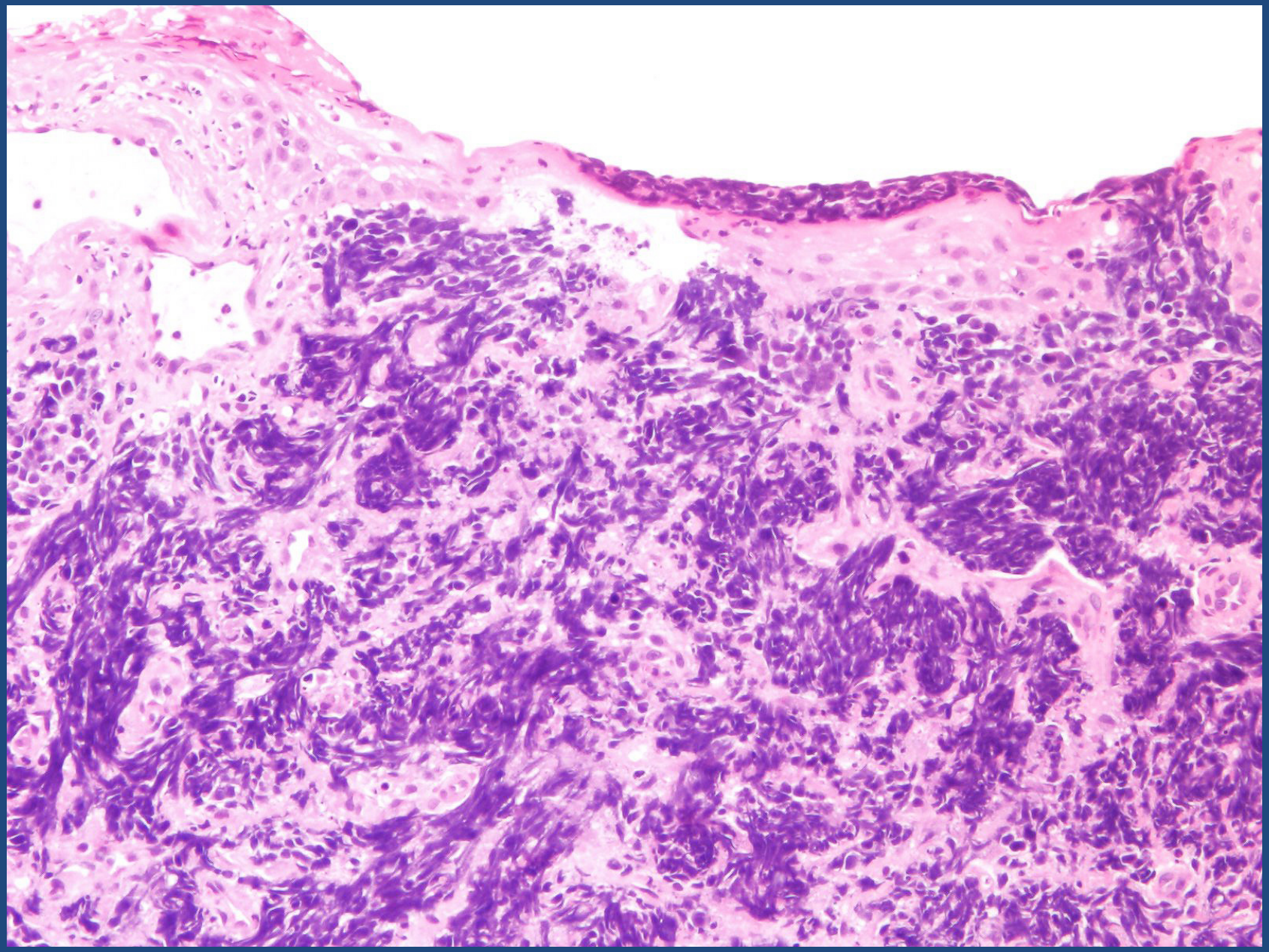

・裸核状の小型異型細胞の増殖を認める

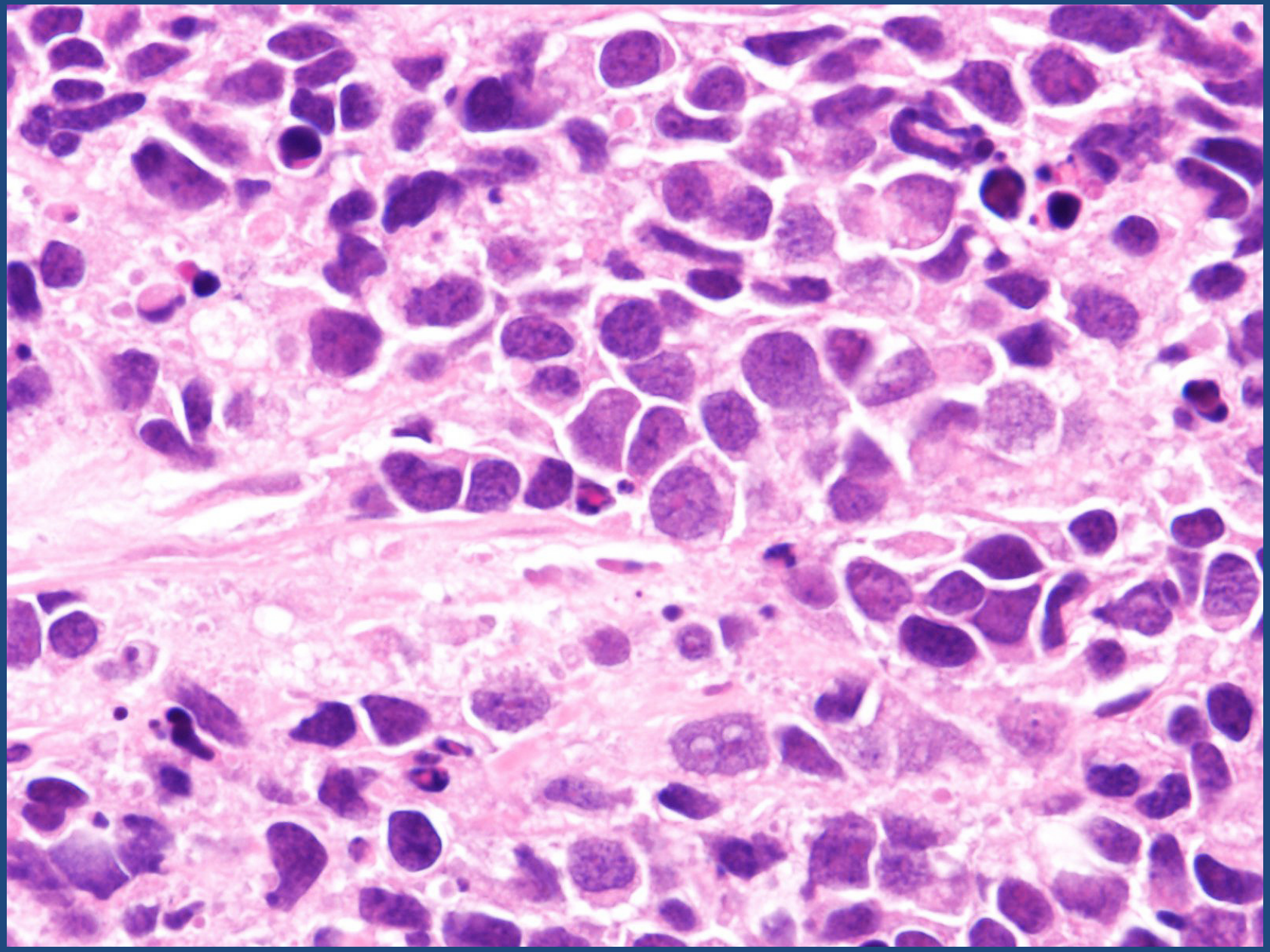

・リボン状および木目込み細工様の配列が見られる

ケラチン(MNF116)

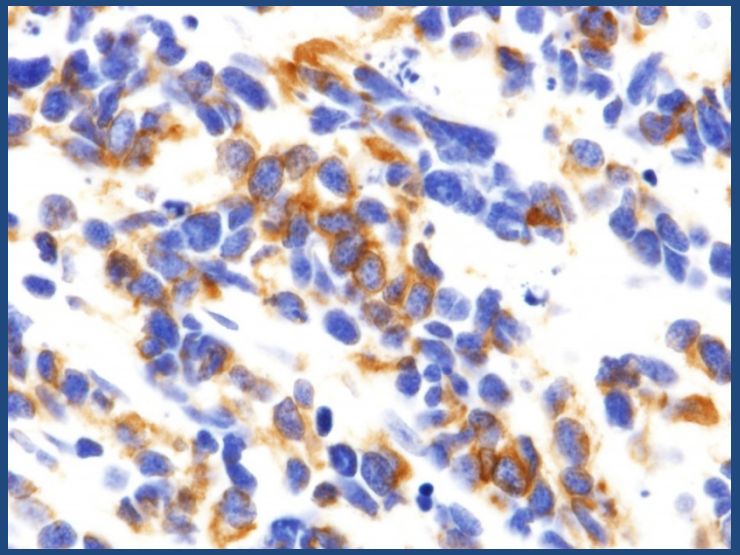

CGA

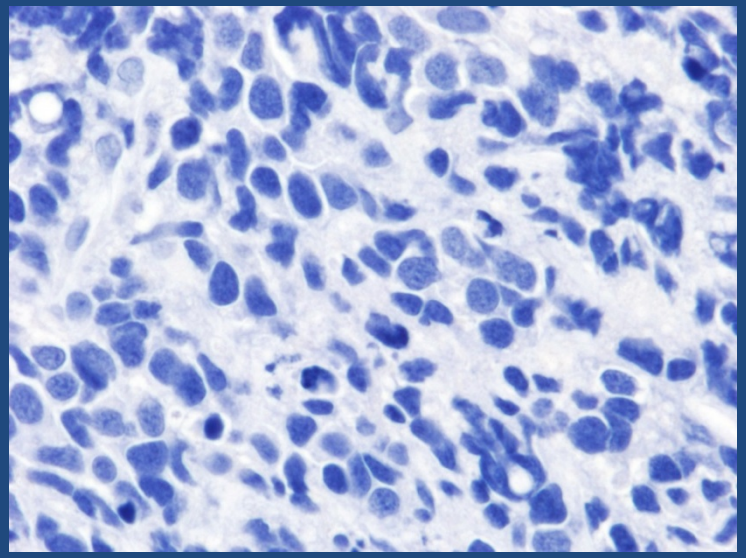

SYP

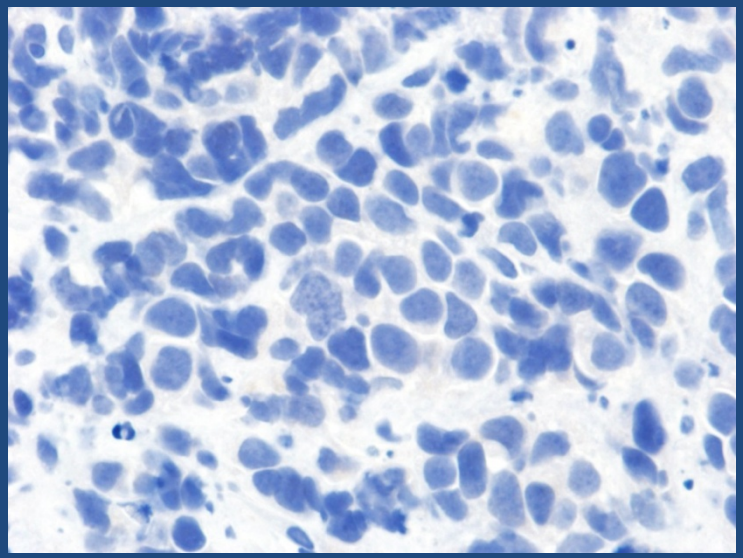

CD56

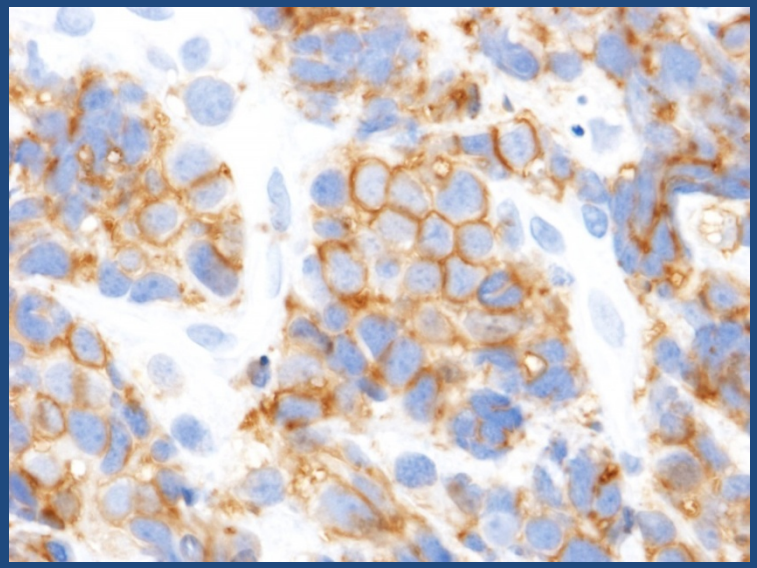

・リンパ球系マーカー陰性，ケラチン（MNF116)陽性，内分泌マーカーではCD56が陽性

組織診断
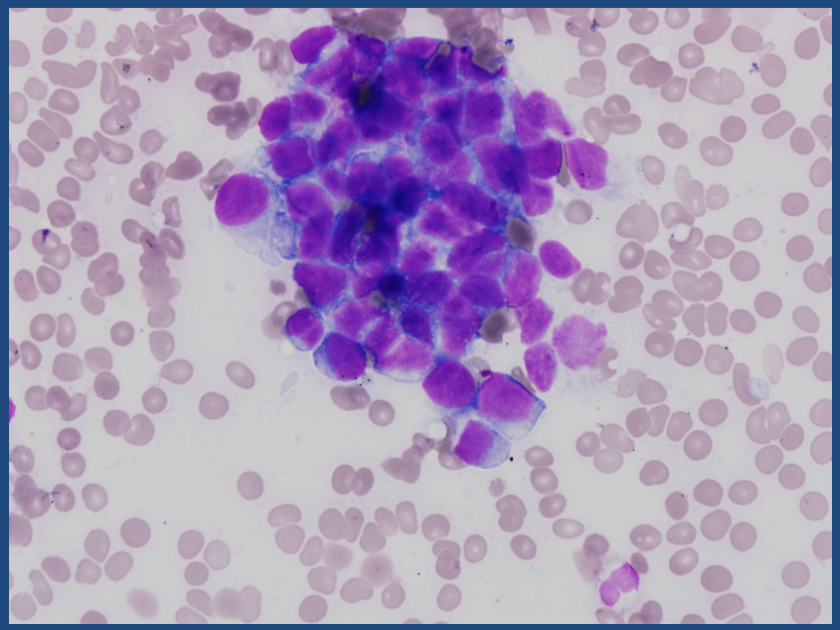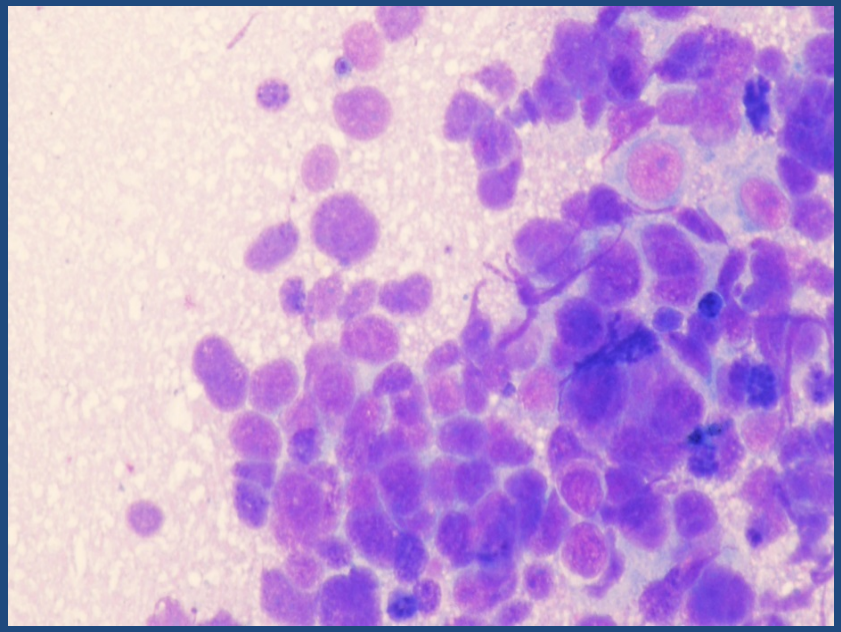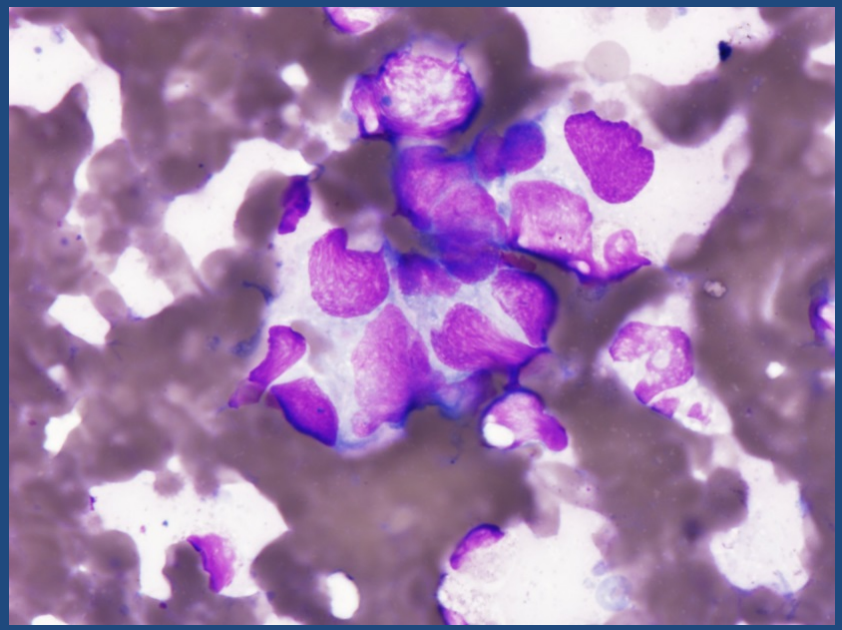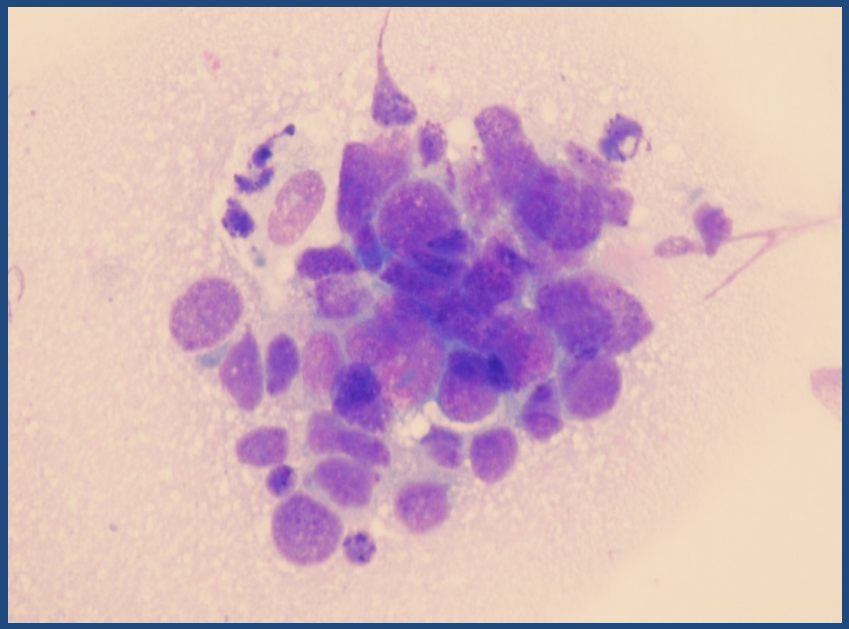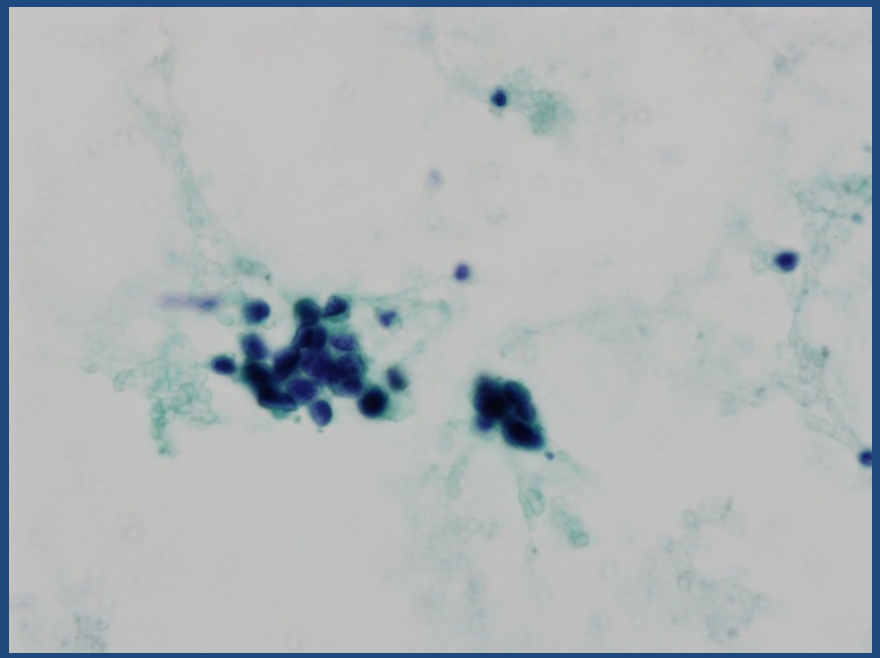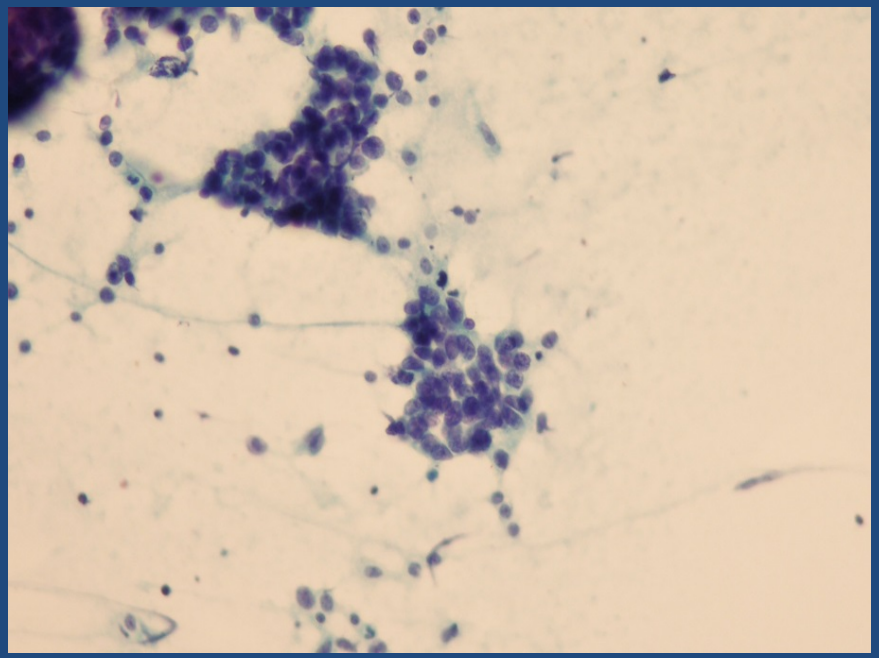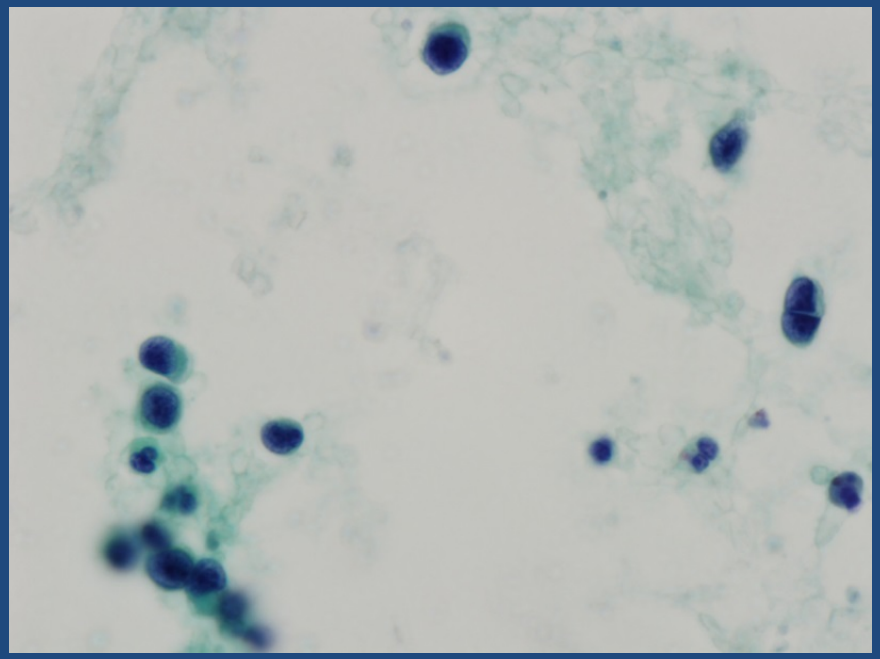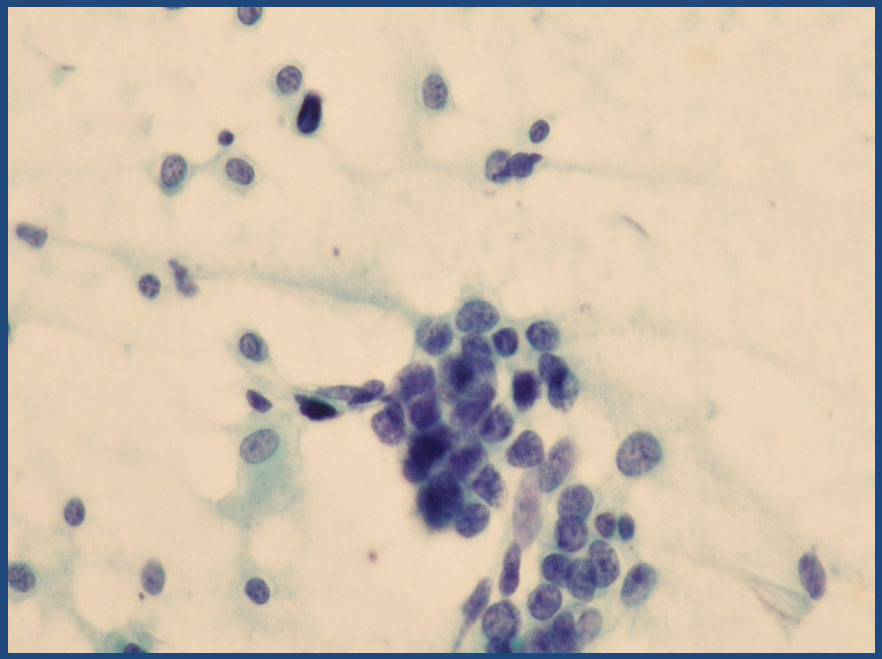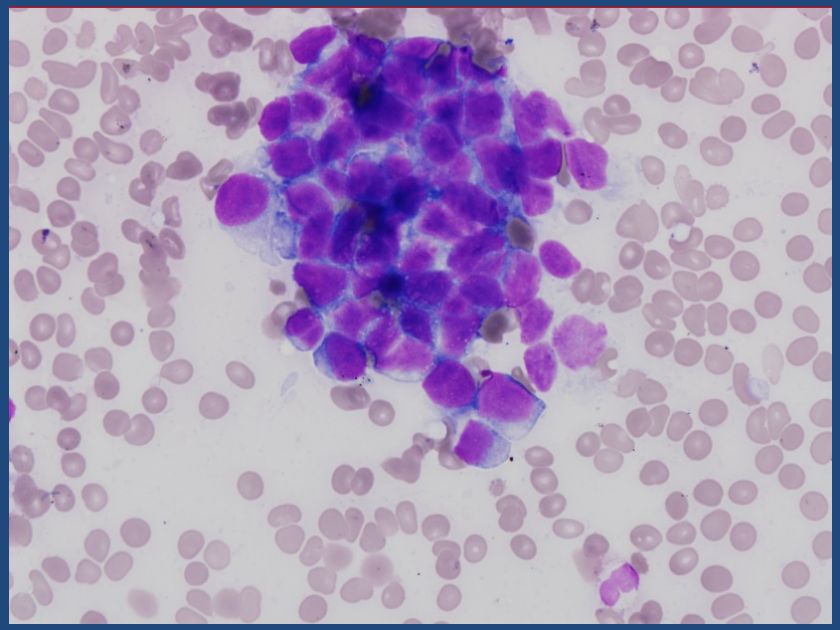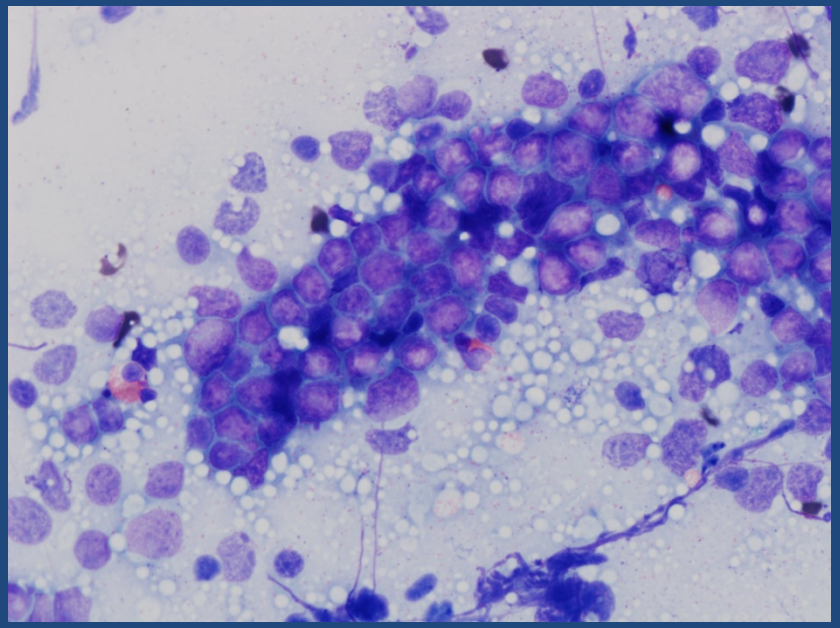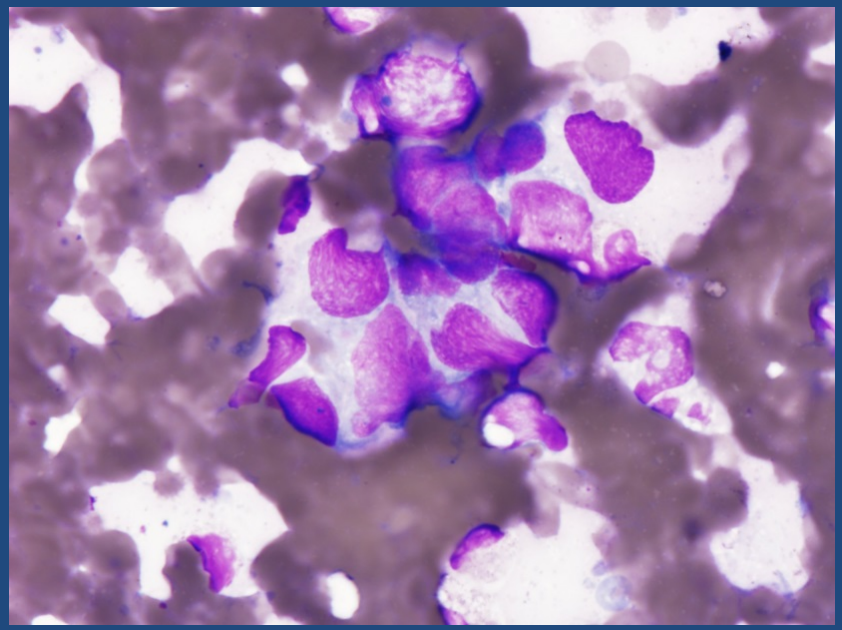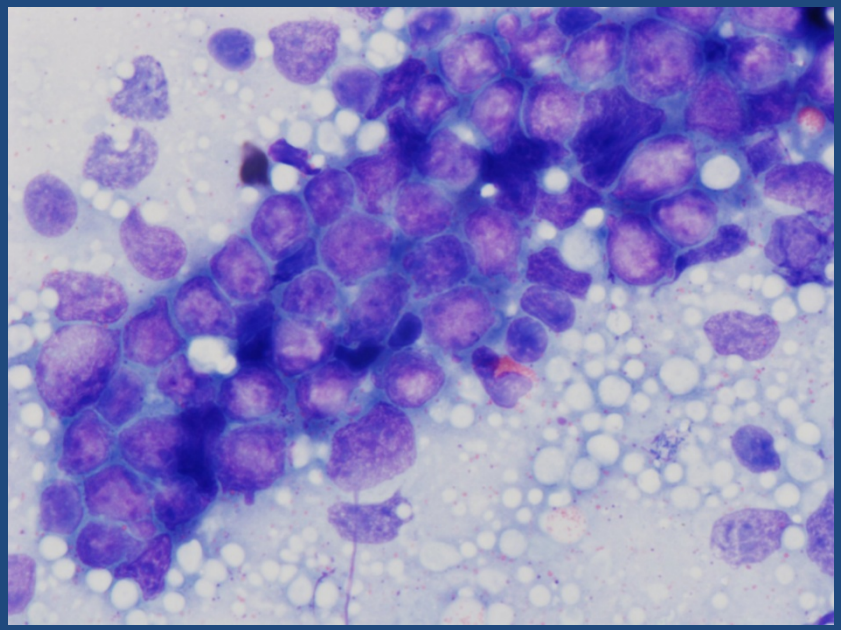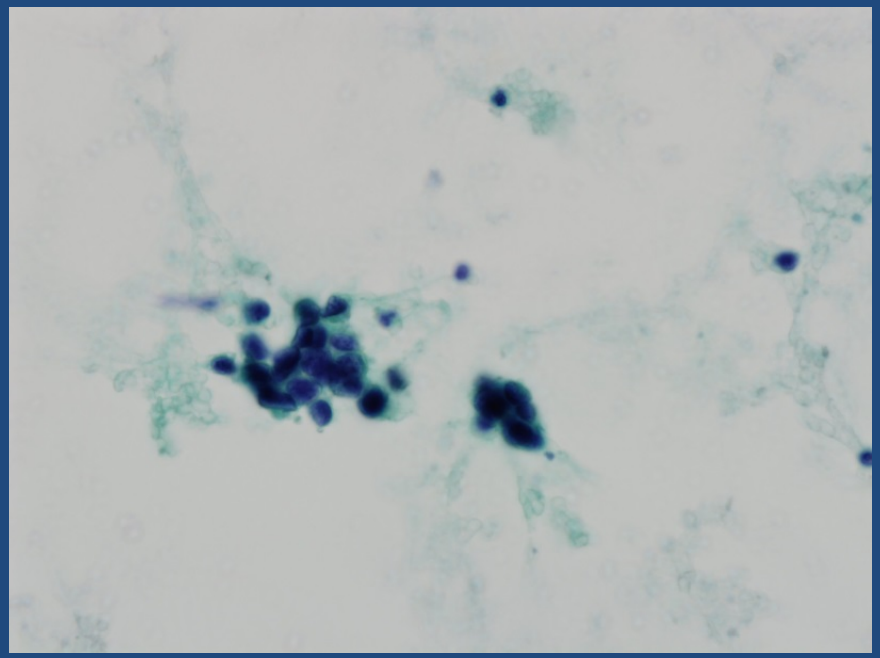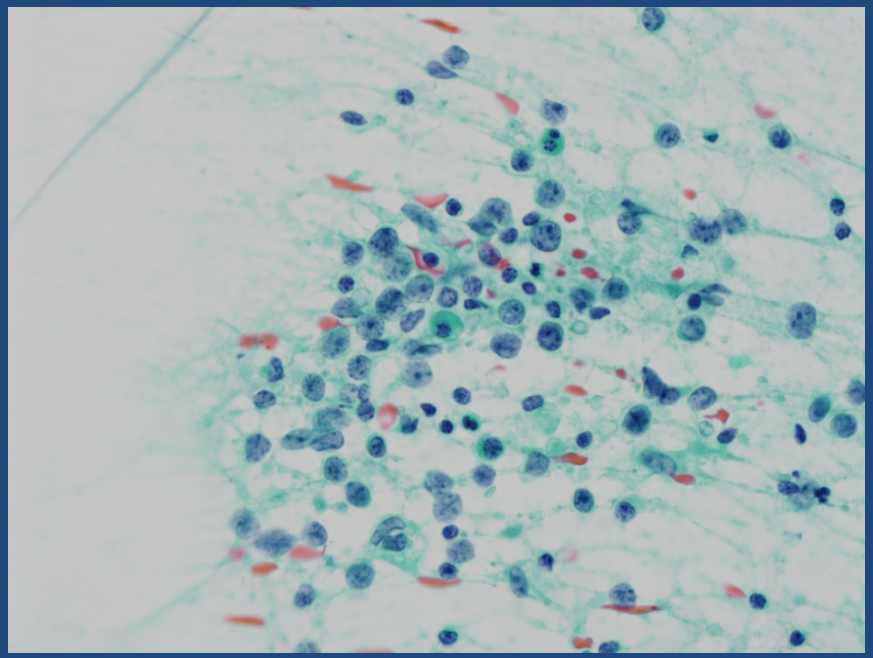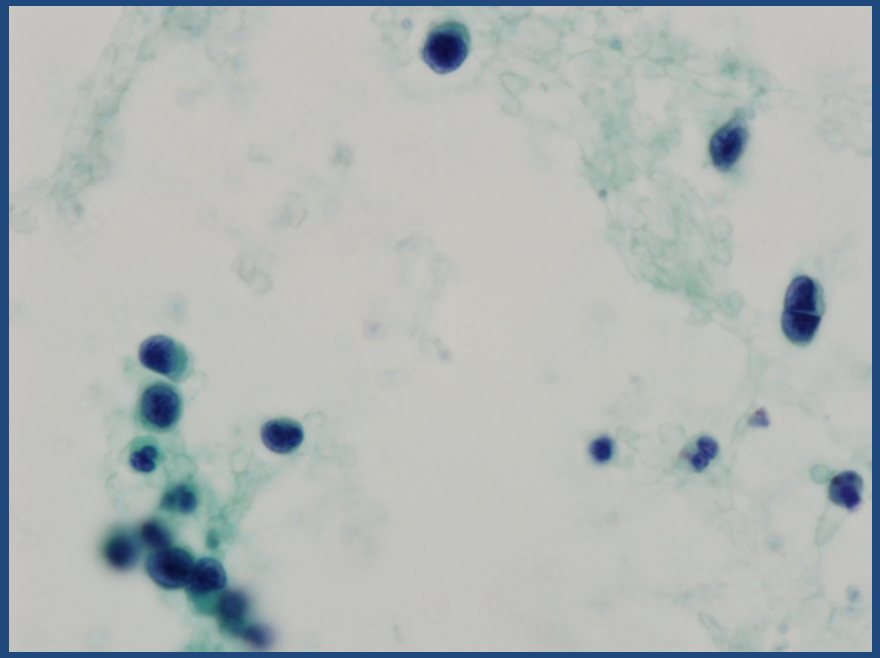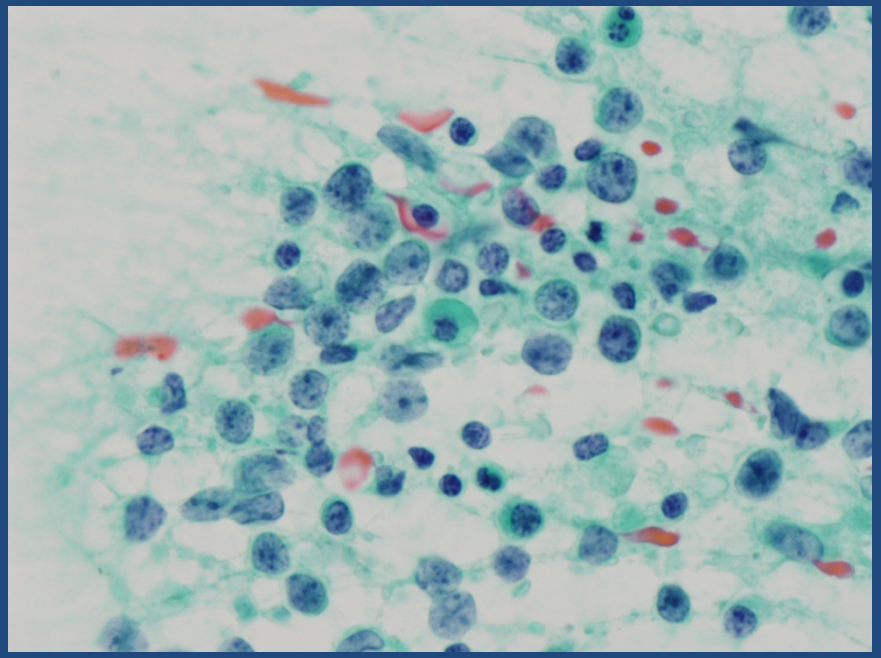
- Small cell carcinoma