

# 第13回大分乳腺診断カンファレンス

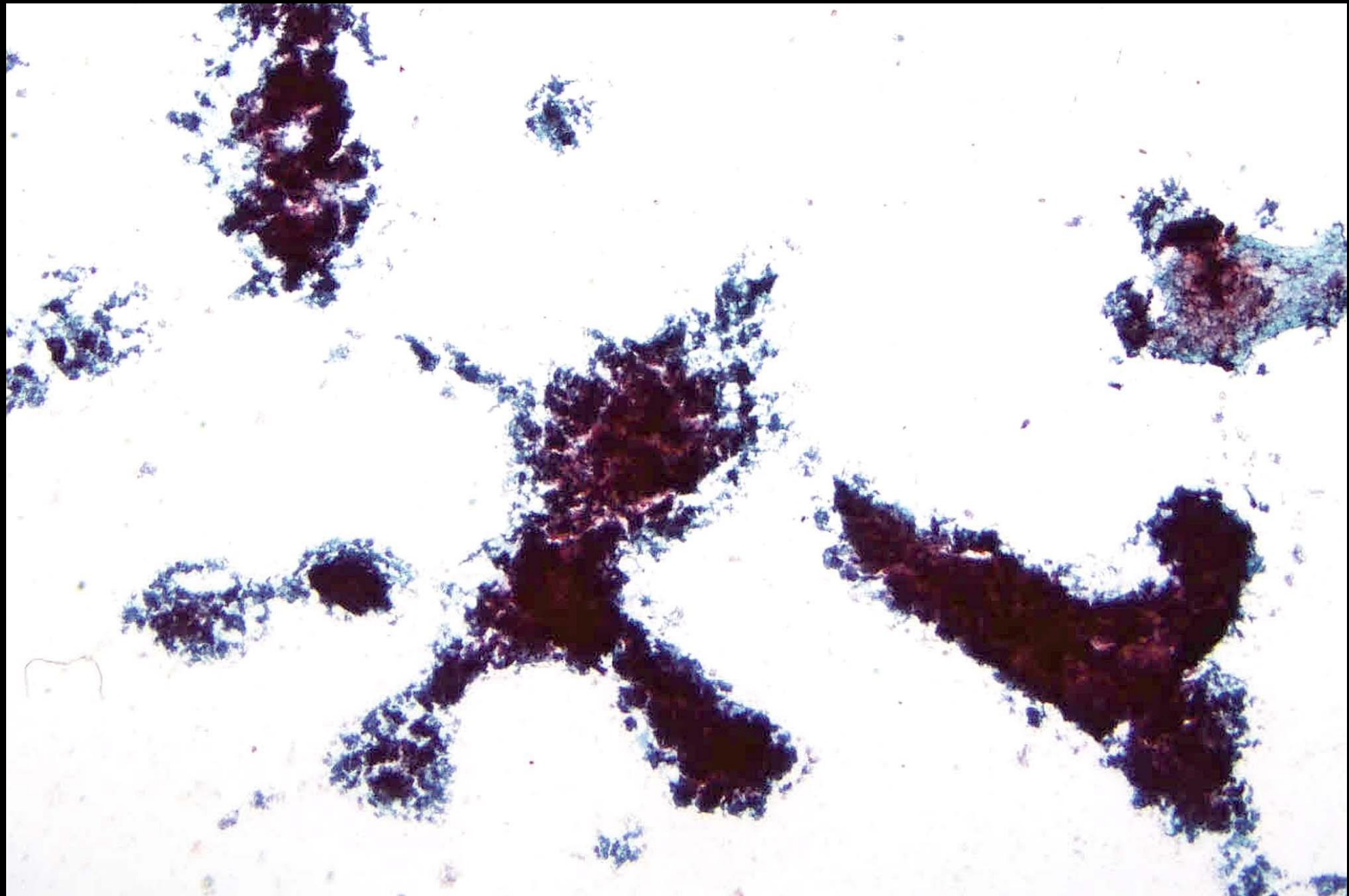
## 細胞診 症例1


2013.10.26 ホルトホール 大分市

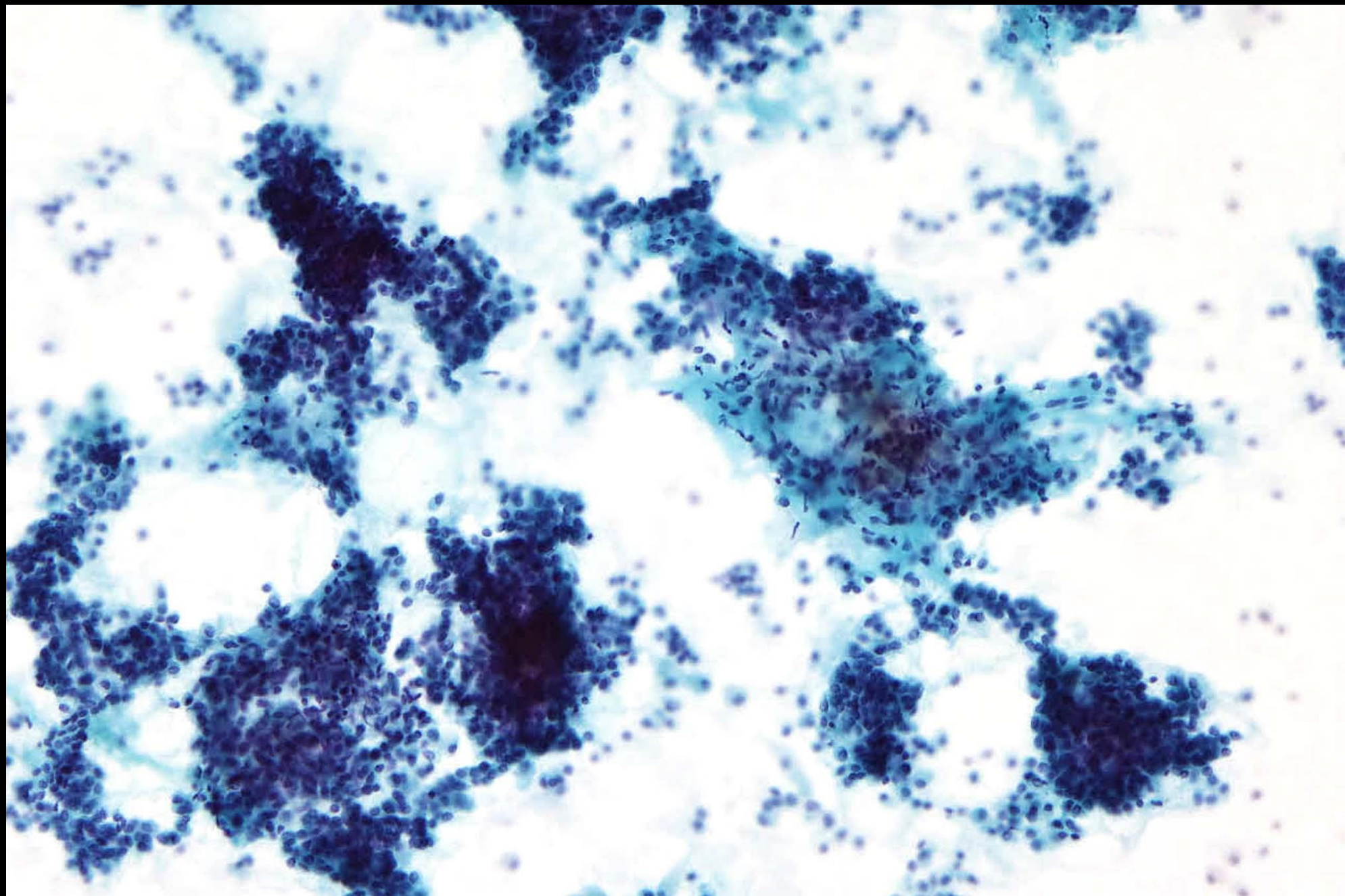
**症例 1 (70代,女性)**

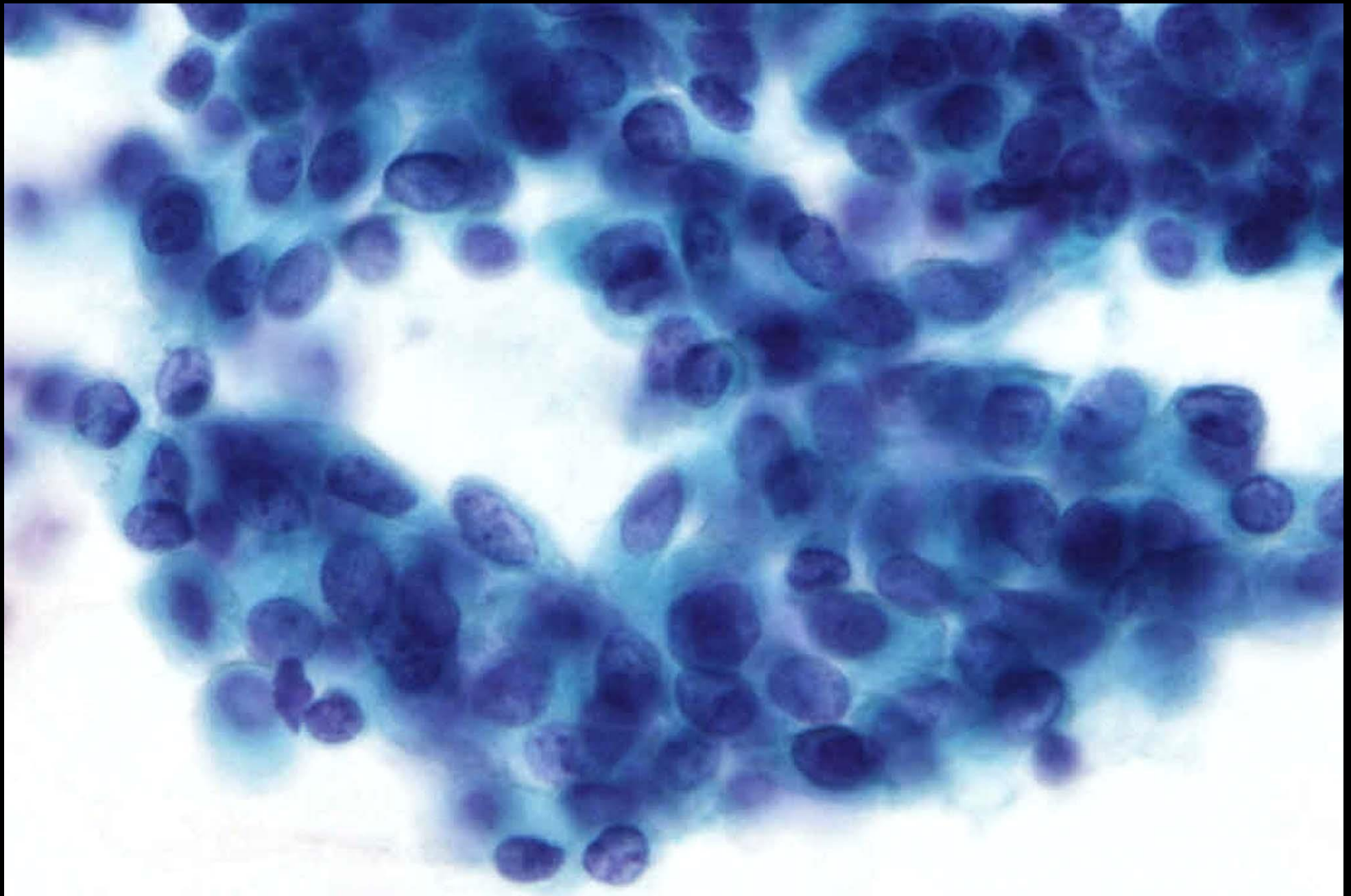
**初回穿刺吸引**

**2009年**





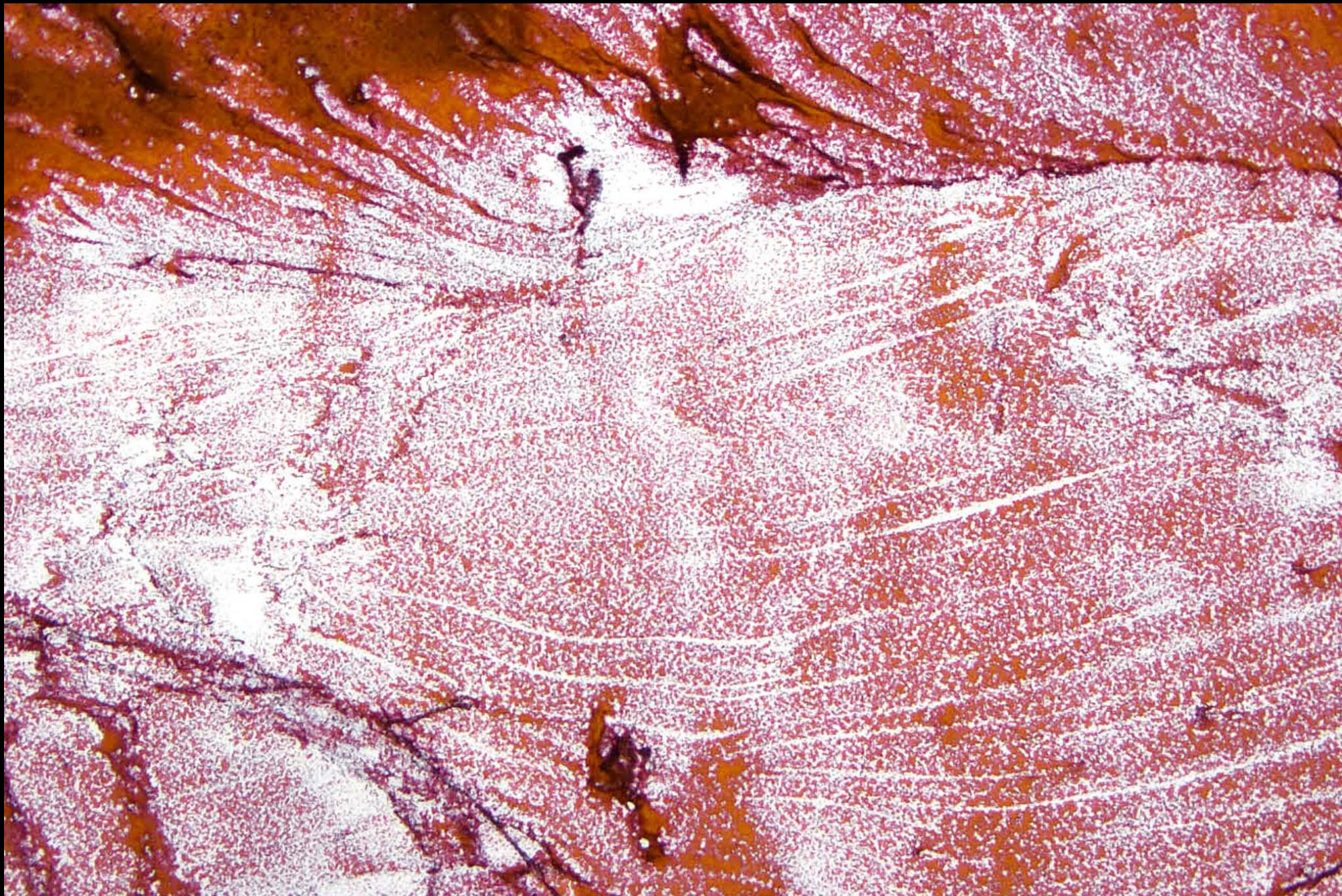




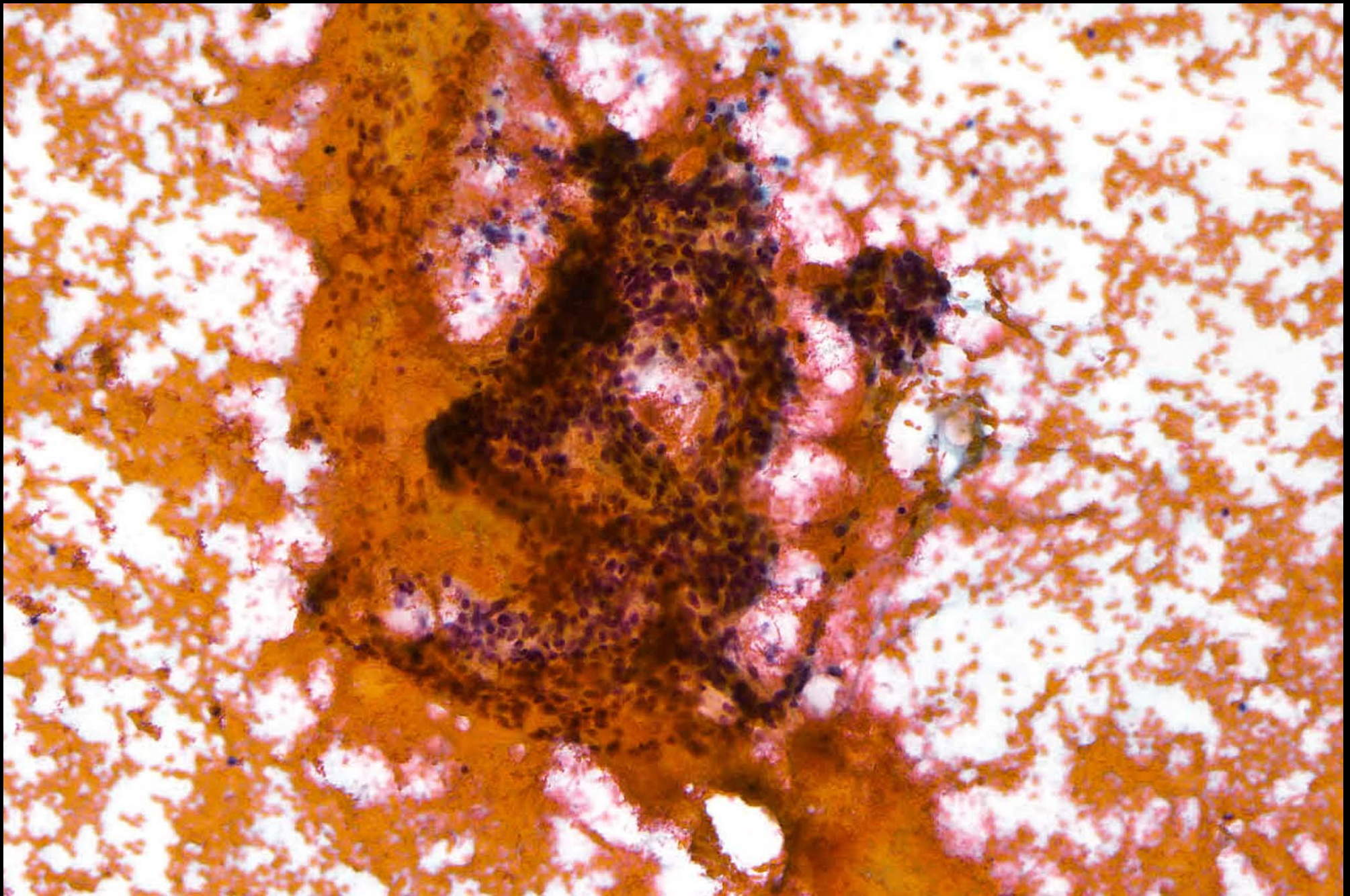
**症例 1 (70代,女性)**

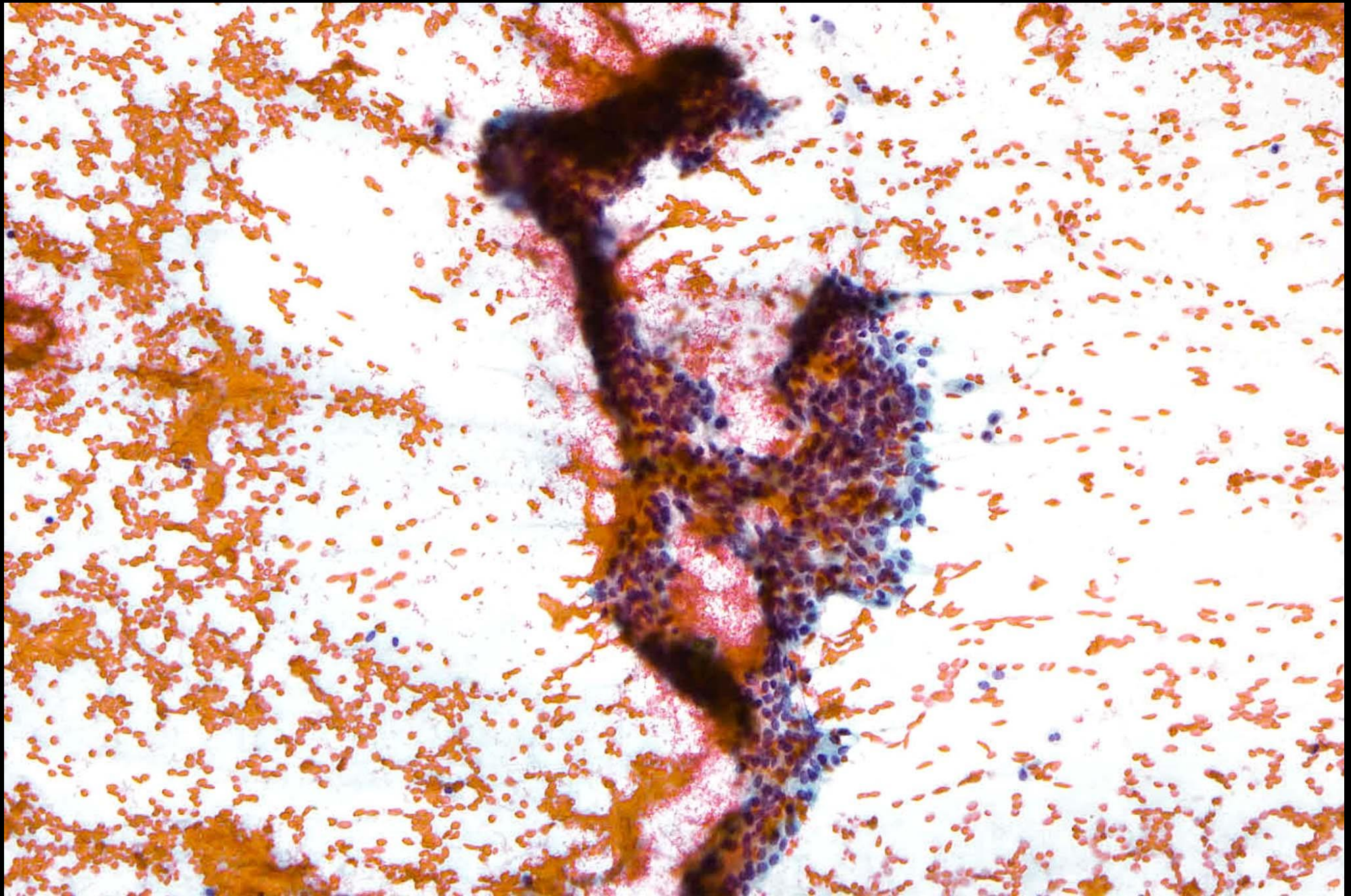
**2回目穿刺吸引**

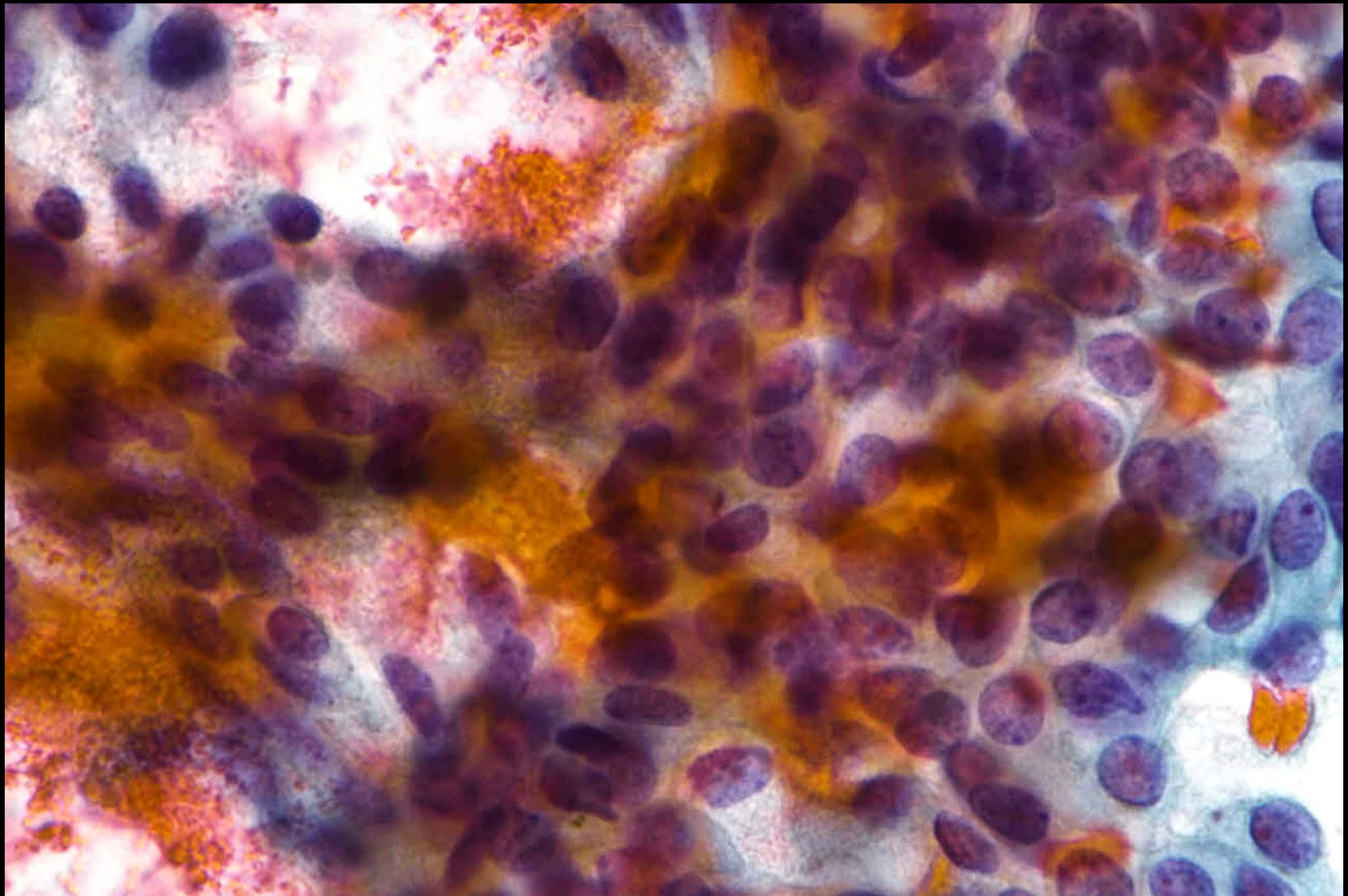
**2010年**

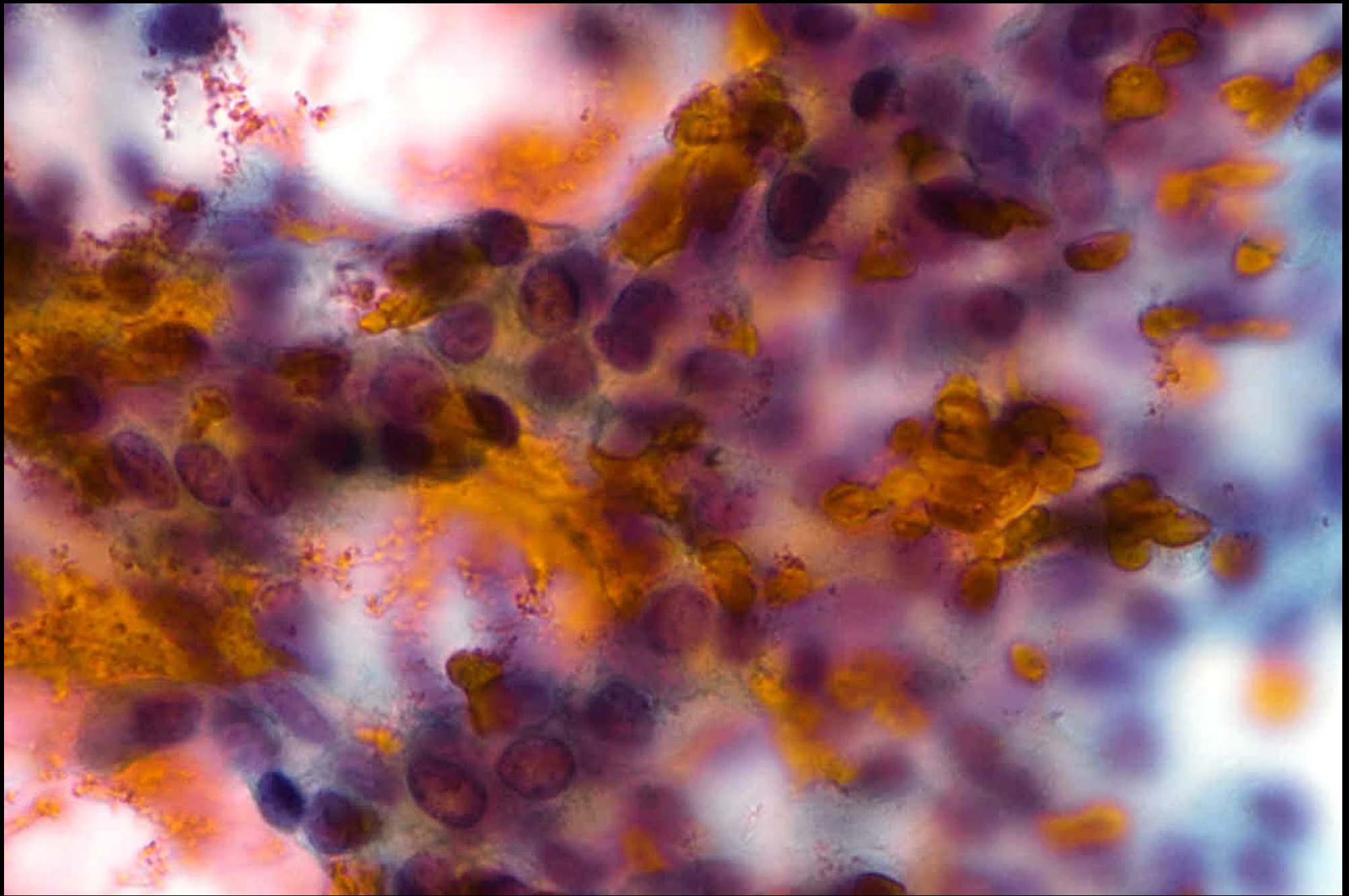












**症例 1(70代, 女性)**

**3回目穿刺吸引**

**南海病院 症例**

