

# 第12回大分乳腺診断カンファレンス

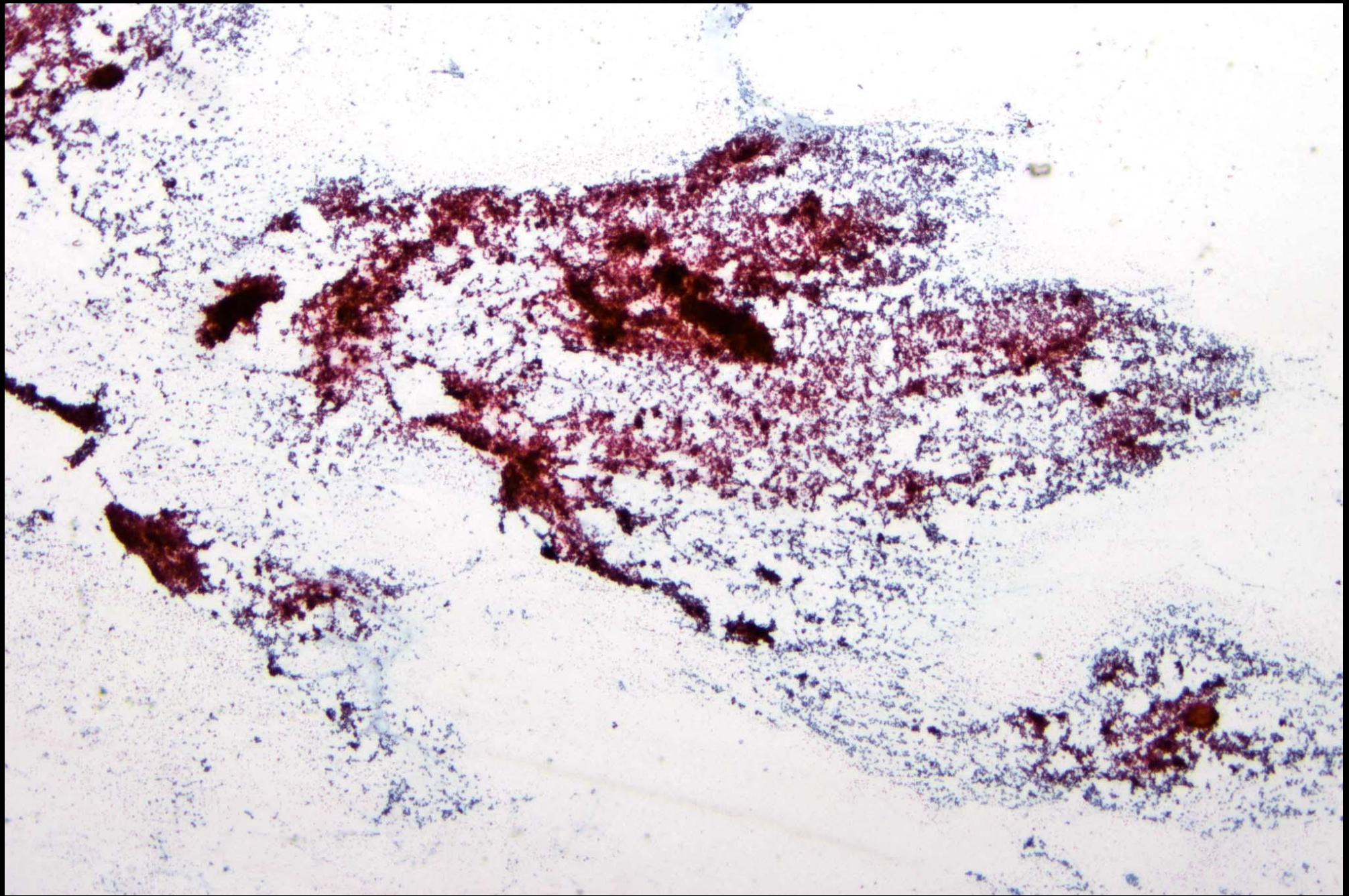
## 細胞診症例

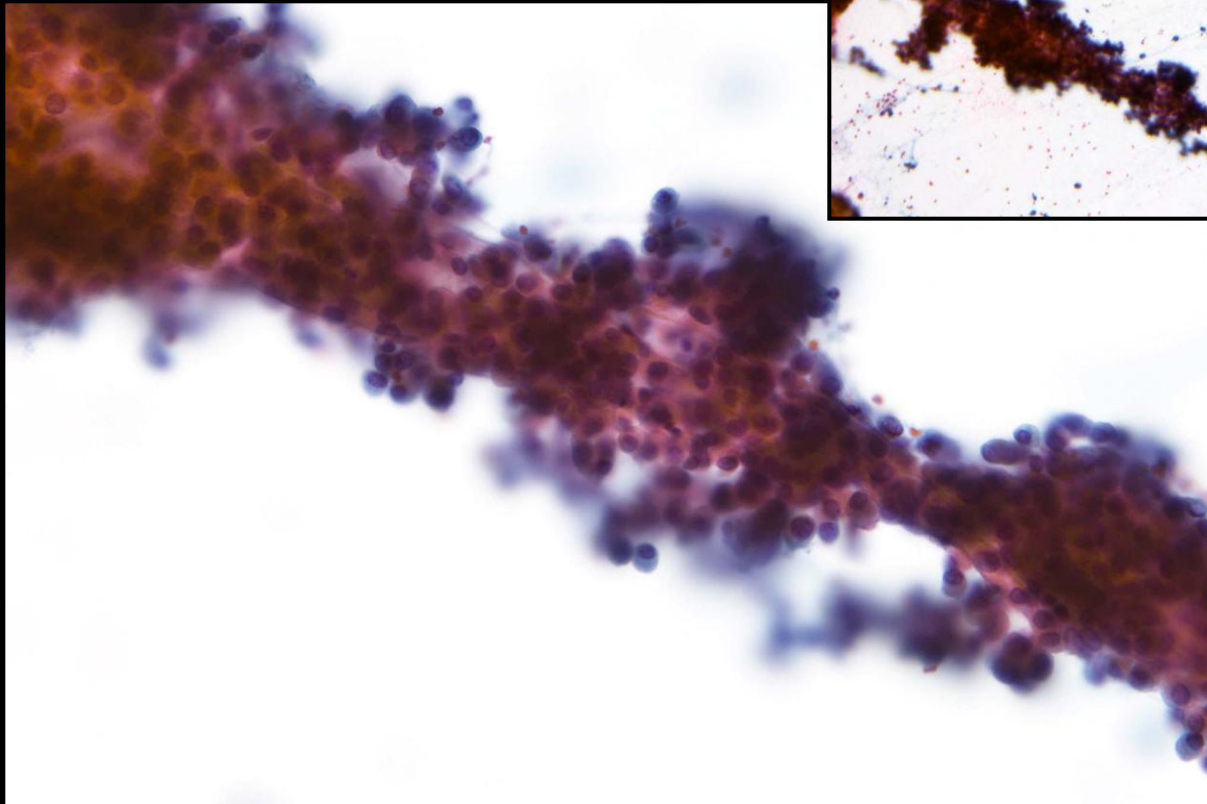
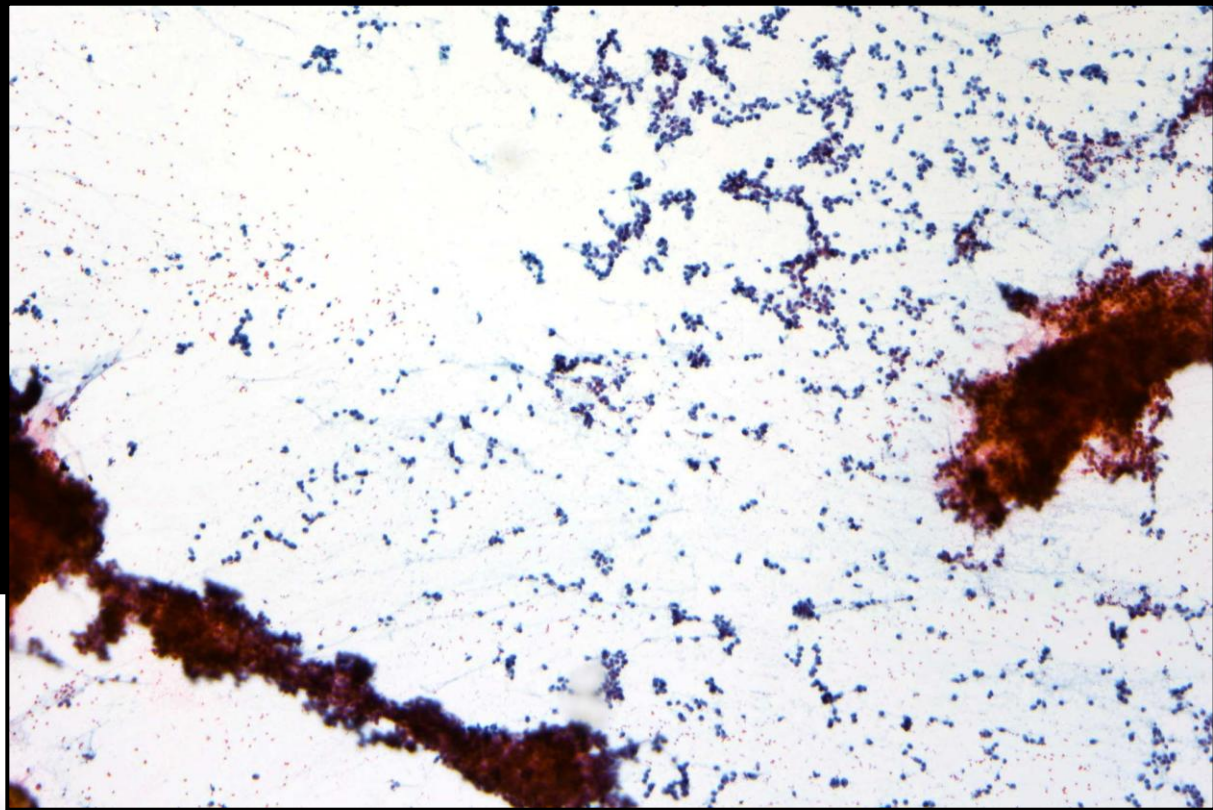
2012. 10. 20 大分国際交流会館 別府市

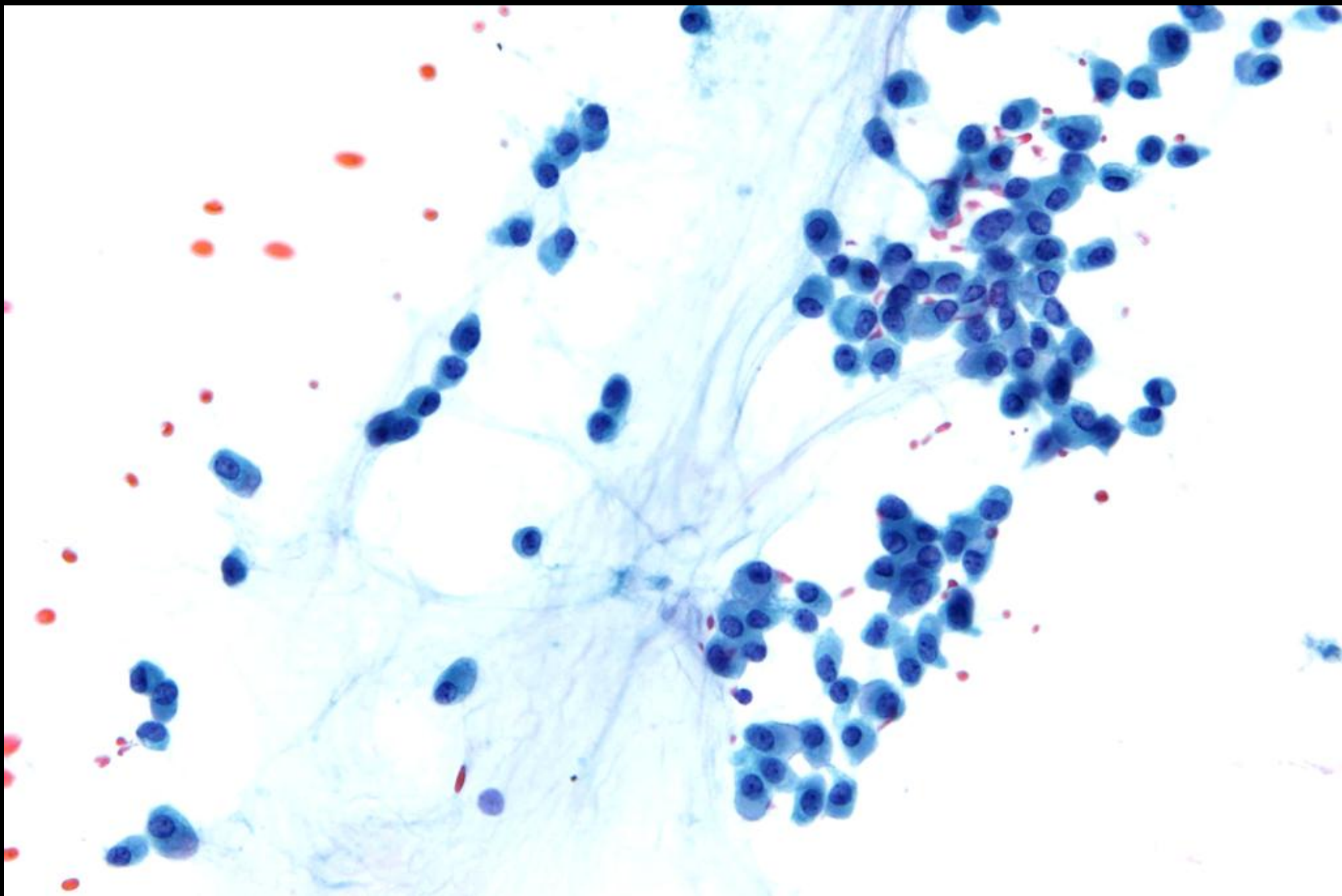
**症例**

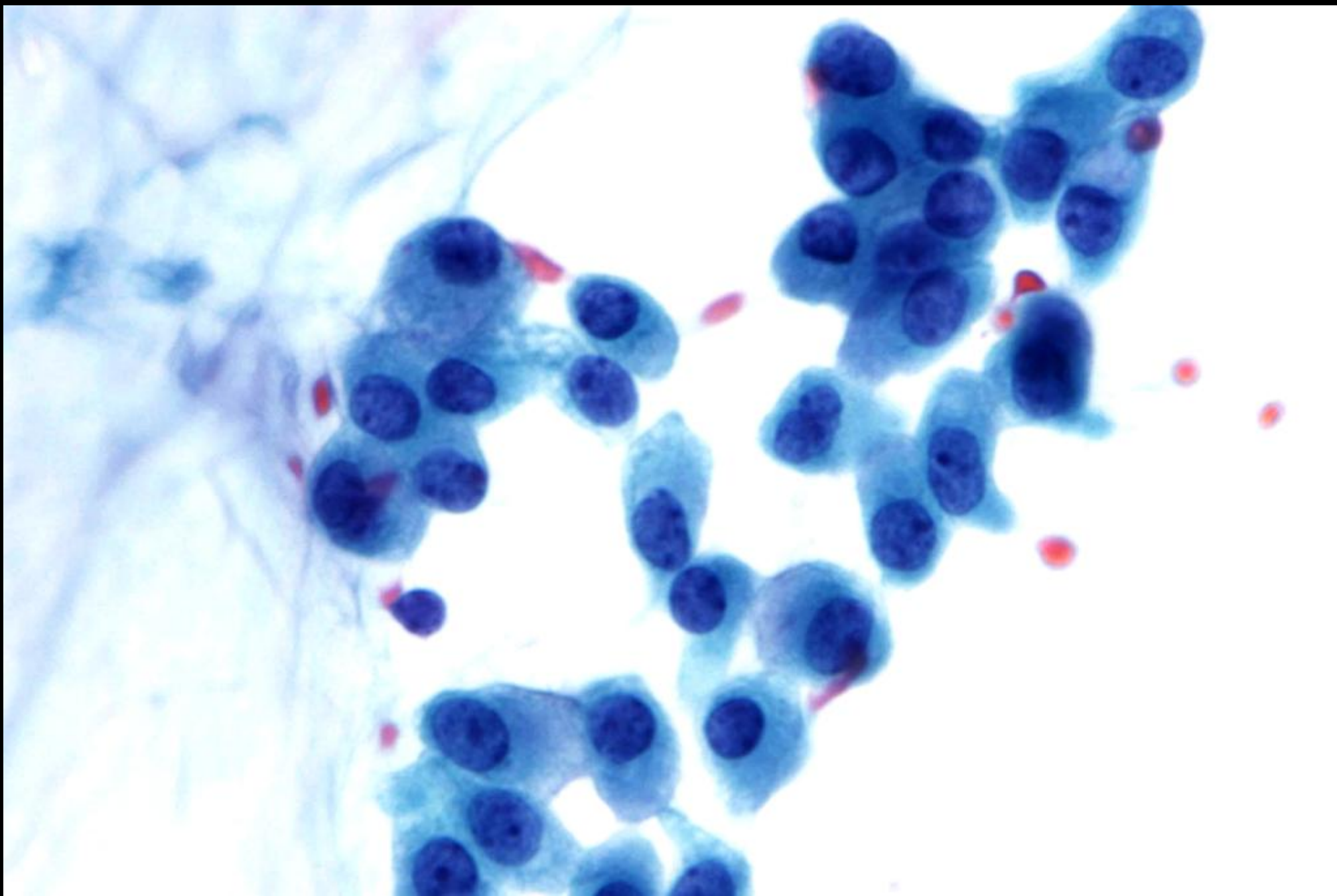
**九州大学病院別府病院**

**藤吉乳腺クリニック**









# 解答

Non invasive  
ductal carcinoma  
(solid papillary carcinoma)